

# Hydatid Disease with Multiple Organ Involvement: A Case Report

Sanja Lovric Kojundzic, Kresimir Dolic, Ante Buca, Stipan Jankovic, Nada Besenski

University Hospital Split, Department of Radiology, Split, Croatia

## Abstract

**Citation:** Kojundzic SL, Dolic K, Buca A, Jankovic S, Besenski N. Hydatid Disease with Multiple Organ Involvement: A Case Report. *Maced J Med Sci.* 2010;3(2):XXX-XXX. doi:10.3889/MJMS.1957-5773.2010.0094.

**Key words:** hydatid disease; heart; brain; computed tomography; magnetic resonance imaging.

**Correspondence:** Kojundzic SL, University Hospital Split, Department of Radiology, Split, Croatia. E-mail: lovric.sanja@gmail.com

Received: 11-Feb-2010; Revised: 15-Mar-2010; Accepted: 16-Mar-2010; Online first: 31-Mar-2010

**Copyright:** © 2010 Kojundzic SL. This is an open-access article distributed under the terms of the Creative Commons Attribution License, which permits unrestricted use, distribution, and reproduction in any medium, provided the original author and source are credited.

**Competing Interests:** The authors have declared that no competing interests exist.

We present a case of 34 years old woman with hydatid disease of the lungs, brain and heart but without liver involvement. The disease started in 2006. as pulmonary hydatidosis of the right posterior inferior lobe. In July 2008, brain surgery was performed due to the hydatid disease located on the right temporoparietal region based on computed tomography (CT) and magnetic resonance imaging (MRI). During the postsurgical recovery she complained of dyspnea. Heart ultrasonography and computed tomography showed hydatid cyst located in the left ventricle. Because of the possibility of the multiple organ involvement, we suggest that postoperative follow-up of patients with previous hydatid disease should include chest radiographs, ultrasonography of the heart and even brain CT and/or MRI as standard methods.

## Introduction

Echinococcosis (or hydatid disease) is the most wide spread serious human parasitic infection in the world caused by two main helminth (cestode) types: *Echinococcus granulosus* and *Echinococcus multilocularis*. It is endemic in areas with tropical or subtropical climates particularly in Mediterranean region, South America, Africa and Australia due to the close association between humans and domestic animals.

Humans become infected through contact with definite host or consumption of contaminated food. After it enters the body, larval stage of *Echinococcus* parasite forms cysts. Since the cysts are very slowly growing, the symptoms are seen several years after primary infection. According to the literature, predominate locations of hydatid cysts are the liver (75%) and lungs (15%), but other organs can also be affected: brain (1-2%), spine (1%) and the orbit (0.2%) [1]. The rare localizations of hydatidosis such as heart, thyroid, spleen, pancreas and

muscles lead to atypical clinical presentation causing difficulties in establishing the diagnosis [2]. Definite diagnosis is mostly based on imaging techniques: ultrasound (US), computed tomography (CT) and magnetic resonance imaging (MRI).

Clinical management of hydatid disease include several approaches: surgery, chemotherapy with benzoimidazole carbamates (mebendazole and albendazole), percutaneous drainage – PAIR (termed puncture, aspiration, injection and reaspiration) with concomitant pre- and post- interventional chemotherapy [3]. Cycle of albendazole treatment is suggested as first choice treatment in patients with no complicated cysts and in patients without contraindications to chemotherapy. Both albendazole (10-15 mg/kg) and mebendazole (40-50 mg/kg) are more effective in cycles of continuous treatment, without intervals. Lung cysts and especially cysts of young people are more responsive to carbamate therapy [4].

We herein report a female patient with surgically and histologically proven hydatid disease of the lungs, followed by multiple brain lesions and the heart at the same time but without liver involvement.

### Case report

A 34 years old woman was admitted to the Department of Neurology, University Hospital Split, complaining of headache and vomiting. A family history revealed that she lives in rural area on a farm with animal husbandry (cows, goats, dogs) and that she underwent coniotomy twelve years ago. She also had right posterior inferior lobectomy because of pulmonary hydatid disease two years ago (Figure 1).

Neurological examination of the patient revealed discrete left supranuclear facial hemiparesis, discrete left-sided hemiparesis and hemihypoesthesia. Plantar reflex on the left side was absent. Routine blood tests and urine analysis showed no abnormalities. Indirect haemagglutination (IHA) test was found positive (1: 512 titer). Brain CT revealed round sharply demarcated hypodense lesions with a diameter of 3.8 and 2.9 cm located on the right temporoparietal region (Figure 2A). These round lesions with hypodense central area showed rim enhancement and caused compression of the brain ventricles together with leftward shift of the midline structures of approximately 1 cm. MRI confirmed three spherical lesions, iso-intense with cerebrospinal fluid, surrounded by few “daughter” lesions producing obvious

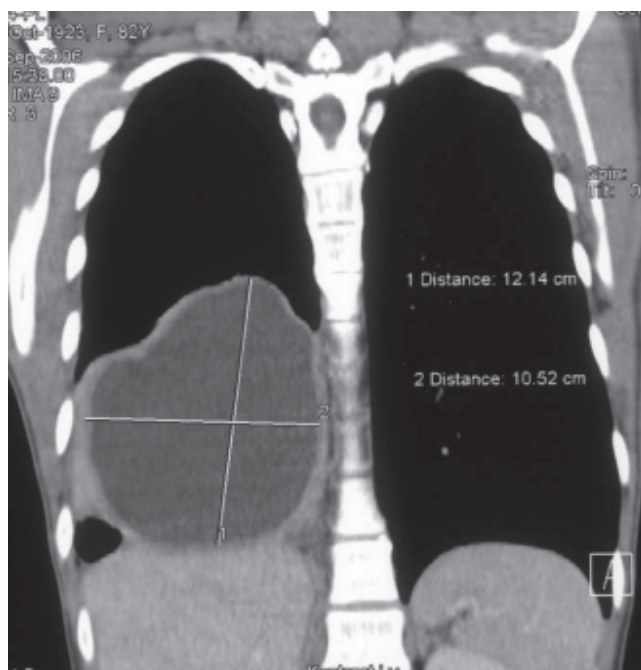

Figure 1: Coronal view of the postcontrast chest CT scan reveals a large hydatid cyst.

mass effect on the brain tissue (Figure 2B). These cystic lesions caused compression of the occipital ventricle together with leftwards shift of the lateral, third ventricle and anterior part of the falx. The MRI also showed temporal ventricle enlargement and mass effect on perimesencephalic structures.

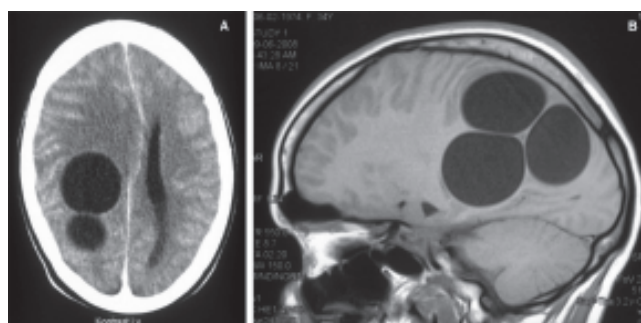


Figure 2: A) Postcontrast axial CT scan of the brain demonstrates cystic mass lesions in the right temporoparietal region with no enhancement, but with mass effect on the brain tissue and midline shift. B) MR sagittal T1 weighted image showed multiple supratentorial cystic lesions.

Abendazole therapy was initiated as recommended by an infectious disease specialist. The patient was then referred to neurosurgery for excision of the cyst. A craniotomy was performed and after wide cortical incision, warm saline was instilled between the

cyst and surrounding brain to remove the cyst without rupture. After surgery she developed osteomyelitis, which was successfully cured with antibiotic therapy. During follow up no neurological deficit was observed but the patient complained on temporary dyspnea. Therefore, she was transferred to Department of Internal Medicine. During physical examination, patient's heart rate was 80/min and blood pressure at 90/60 mmHg. Cardiac auscultation revealed normal heart sounds without pathologic murmurs. Pulmonary auscultation was also normal. Transthoracic ultrasonography showed cystic mass with dimensions of 2.0 x 1.5 cm (Figure 3A) in the left ventricular wall, attached to the mitral valvulae and causing mild mitral regurgitation. Multi-slice computed tomography (MSCT) of the heart confirmed diagnosis of the cardiac echinococcosis demonstrating hypodense cystic lesion with dimensions of 3.0 x 1.1 x 1.6 cm in the apical segment of the left ventricle (Figure 3B).

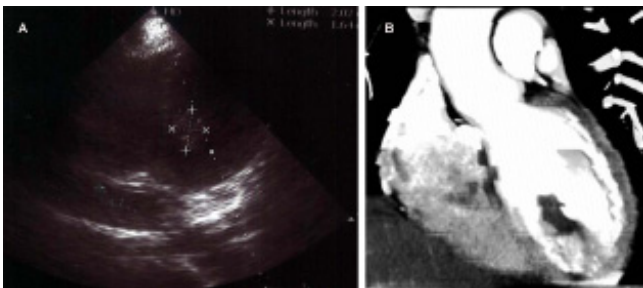


Figure 3: A) Transthoracic ultrasonography of the heart shows small cyst of the left ventricular wall near the mitral valvulae. B) MSCT of the heart, VRT reconstruction, demonstrates hypodense cystic lesion in the apical segment of the left ventricle.

Therefore, she was admitted to Department of Cardiac Surgery for the removal of the cyst. Open cardiac surgery involved a median sternotomy followed by the cannulation of the aorta and bicaval veins and cardiopulmonary bypass. The cyst content was aspirated and cyst walls removed from the papillary muscle of the left ventricle. The ventriculotomies were closed. Postsurgical pathological and microbial examination confirmed the diagnosis of *Echinococcus granulosus*.

After the surgery, anticoagulant therapy was introduced and the albendazole therapy resumed. There were no complications during or after the surgery. The patient is currently closely supervised and reports no abnormalities.

## Discussion

Echinococcosis or hydatid disease is caused by the larval stage of *Echinococcus granulosus* and is manifested in humans, the intermediate host, by the development of cysts in the liver, lungs, heart and brain. Humans acquire disease by ingesting food or liquids contaminated with definitive hosts' feces containing eggs. After ingestion, the liberated eggs pass through the intestinal wall into the portal system and settle in the liver. The embryos that aren't trapped in the liver, may reach and implant in the lungs or even enter systemic circulation [5]. It is estimated that 10-20% of the parasites escape the liver-lung filter and develop in various organs [2]. Many hypotheses tried to explain the reasons why the parasite avoids the pulmonary-liver filter, but no one really proved [6].

Since the hydatid cysts are characterized by very slow growth they are well tolerated during a long period. Clinical manifestations are usually seen several years after infection developing as a consequence of the space-occupying effect of the enlarging cyst in a confined space [7]. It has been shown that the cysts grow faster in elastic compressible organs like lung and brain than in liver (ratio of growth is 3:1) [5]. The unique findings of the present case include multi-organ involvement (lungs, brain, heart at the same time) without liver cysts.

The first manifestation of the disease in the present case was pulmonary hydatidosis. The lung is reported to be the most frequent site of the hydatidosis in children whereas it is the second common site of the infestation in adults [8]. The high incidence in children is probably due to the incidental detection on chest radiographs during investigation of other respiratory infections [9].

The pulmonary hydatidosis has a predilection for the right lower lobes of the lung as it was in the present case [9]. Radiologically, hydatid cysts in lungs appear as well-defined masses indistinguishable from lesions such as granulomas, abscesses, bronchogenic cysts, arteriovenous malformations and solitary metastases [10]. They are shown on CT as lesions with smooth walls and homogenous contents of near-water density.

Cerebral hydatidosis is a rare form of echinococcosis [11] and is considered a childhood disease because it affects children eight times more commonly than adults [12]. The most frequent location is the parietal lobe region (territory of the middle cerebral artery). Cerebral hydatidosis is usually presented as a single intracranial lesion and multiple lesions are extremely rarely seen [13]. The patients remain in remarkably good condition for a long period of time, with only a minor neurological deficit, in

spite of the large size of the cyst. This is due to the slow growth of the cyst without perifocal oedema [11]. The most common manifestations of the cerebral echinococcosis are headache and vomiting. Other symptoms include hemiparesis, seizures, visual disturbances, gait disorders, papilloedema [14]. The differential diagnosis of the intracerebral hydatid disease include cystic lesions such as porencephalic cyst, cystic tumor of the brain and pyogenic abscessus [10,14].

In present case, the cerebral hydatidosis was very unusual, with multifocal lesions located supratentorially, in temporoparietal region. The clinical features of the disease in our case were mild despite the size, number and location of the lesions.

The heart contractions provide natural resistance to viable hydatid cysts so they affect heart very rarely (0.2 to 0.3% of the cases). Predominant location is the left ventricle (75%), followed by the right ventricle (18%) and the interventricular septum (7%) [15]. Extremely rare localization of the cyst, which was seen in our patient, is papillary muscle that sometimes may require the excision of the valve [16].

The increase in volume and compression of the adjoining heart structures is responsible for the appearance of symptoms like chest pain, palpitation, dizziness, lethargy, dyspnea and syncope. The clinical presentation of the heart hydatidosis may be nonspecific, mimicking valvular lesions, intracardiac mass, or even heart failure [17].

In present case the dyspnea was the only symptom of the heart involvement although the localization of the cyst in the papillary muscle of the left ventricle was expected to give more serious symptoms.

Very serious complication of the hydatid disease is rupture of the cyst that can lead to sudden death or anaphylactic shock. The rupture of hydatid cyst is very rare and can occur spontaneously or iatrogenically, following serious injuries, or even minor trauma [17]. In the case of the cardiac echinococcosis, the rupture may cause acute or chronic pulmonary embolism, conduction disturbance, arrhythmia, acute arterial occlusion, myocardial ischemia and infarction, or even cardiac tamponade [18]. If other organs are affected, the mechanisms of sudden death include pulmonary hypertension, peritonitis, cerebral ischemia or infarction, intracerebral mass effect, seizures and obstructive hydrocephalus [18]. For echinococcosis, echocardiography in combination with MRI or CT scans is the most important for establishing diagnosis [15]. Serologic test are useful for diagnosis but in some patients, because

of insufficient immune response, the results may be negative [19]. Therefore, antibody test may be only supportive, and negative result does not rule out echinococcosis. Final diagnosis is based on epidemiological data, clinical picture, imaging studies and serological tests.

The pharmacologic therapy consists mainly of abendazole or mebendazole which should be used peri- and postoperatively to prevent spreading or recurrence of the disease [3]. Due to the fatal consequences of possible cyst rupture, surgical excision is usually the treatment of choice, although it may not be possible in some cases because of the proximity of vital structures.

## Conclusion

Based on present case it should be taken into account that the patients with a history of previous hydatid lung disease may have other organs affection. Therefore, beside the chest radiographs, the postoperative controls of those specific patients should include ultrasonography of the heart and even brain CT and/or MRI as standard methods. Therefore the correct diagnosis can be made earlier followed by specific treatment to avoid severe complications.

## References

1. Iyigun O, Uysal S, Sancak R, Hokelek M, Uyar Y, Bernay F, et al. Multiple organ involvement hydatid cysts in a 2-year-old boy. *J Trop Pediatr*. 2004;50(6):374-6. [doi:10.1093/tropej/50.6.374](https://doi.org/10.1093/tropej/50.6.374) PMID:15537728.
2. Versaci A, Scuderi G, Rosato A, Angio LG, Oliva G, Sfuncia G, et al. Rare localizations of echinococcosis: personal experience. *ANZ J Surg*. 2005;75(11):986-91. [doi:10.1111/j.1445-2197.2005.03588.x](https://doi.org/10.1111/j.1445-2197.2005.03588.x) PMID:16336394.
3. Park KH, Jung SI, Jang HC, Shin JH. First successful puncture, aspiration, injection, and re-aspiration of hydatid cyst in the liver presenting with anaphylactic shock in Korea. *Yonsei Med J*. 2009;50(5):717-20. [doi:10.3349/yjm.2009.50.5.717](https://doi.org/10.3349/yjm.2009.50.5.717) PMID:19881979.
4. Siracusano A, Teggi A, Ortona E. Human cystic echinococcosis: old problems and new perspectives. *Interdiscip Perspect Infect Dis*. 2009;2009:474368. PMID:19888428.
5. Czermak BV, Akhan O, Hiemetzberger R, Zelger B, Vogel W, Jaschke W, et al. Echinococcosis of the liver. *Abdom Imaging* 2008;33(2):133-43. [doi:10.1007/s00261-007-9331-0](https://doi.org/10.1007/s00261-007-9331-0) PMID:17912581.

6. Moro P, Schantz PM. Echinococcosis: a review. *Int J Infect Dis.* 2009;13(2):125-33. doi:10.1016/j.ijid.2008.03.037 PMID:18938096.
7. Kovoov JM, Thomas RD, Chandrashekhar HS, Jayakumar PN, Pillai S, Shankar SK. Neurohydatidosis. *Australas Radiol.* 2007;51(5):406-11. doi:10.1111/j.1440-1673.2007.01860.x PMID:17803790.
8. Olmez D, Babayigit A, Arslan H, Uzuner N, Ozturk Y, Karaman O, et al. Multiorgan involvement in a pediatric patient with hydatid disease. *J Trop Pediatr.* 2008;54(6):417-9. doi:10.1093/tropej/fmn054 PMID:18593736.
9. Mavridis G, Livaditi E, Christopoulos-Geroulanos G. Management of hydatidosis in children. Twenty-one year experience. *Eur J Pediatr Surg.* 2007;17(6):400-3. doi:10.1055/s-2007-989269 PMID:18072024.
10. Andronikou S, Welman CJ, Kader E. Classic and unusual appearances of hydatid disease in children. *Pediatr Radiol.* 2002;32(11):817-28. doi:10.1007/s00247-002-0785-5 PMID:12389111.
11. Tlili-Graies K, El-Ouni F, Gharbi-Jemni H, Arifa N, Moulahi H, Mrad-Dali K, et al. [Cerebral hydatid disease: imaging features]. *J Neuroradiol.* 2006;33(5):304-18. doi:10.1016/S0150-9861(06)77288-1 PMID:17213758.
12. Taori K, Sanyal R, Rathod J, Mahajan S, Jajoo G, Saxena V, et al. CT appearances of hydatid disease at various locations. *Australas Radiol.* 2006;50(4):298-305. doi:10.1111/j.1440-1673.2006.01588.x PMID:16884413.
13. Senturk S, Oguz KK, Soylemezoglu F, Inci S. Cerebral alveolar echinococcosis mimicking primary brain tumor. *AJNR Am J Neuroradiol.* 2006;27(2):420-2. PMID:16484422.
14. Bükte Y, Kemaloglu S, Nazaroglu H, Ozkan U, Ceviz A, Simsek M. Cerebral hydatid disease: CT and MR imaging findings. *Swiss Med Wkly.* 2004;134(31-32):459-67. PMID:15389350.
15. Dursun M, Terzibasoglu E, Yilmaz R, Cekrezi B, Olgar S, Nisli K, et al. Cardiac hydatid disease: CT and MRI findings. *AJR Am J Roentgenol.* 2008;190(1):226-32. doi:10.2214/AJR.07.2035 PMID: 18094316.
16. Sensoz Y, Ozkokeli M, Ates M, Akcar M. Right ventricle hydatid cyst requiring tricuspid valve excision. *Int J Cardiol.* 2005;101(2):339-41. doi:10.1016/j.ijcard.2004.01.043 PMID:15882692.
17. Zobel C, Kuhn-Regnier F, Kruger K, Gerharz M, Schneider CA, Muller-Ehmsen J, et al. Echinococcus cyst located in the interventricular septum. *Clin Res Cardiol.* 2006;95(11):600-4. doi:10.1007/s00392-006-0428-1 PMID:16897142.
18. Byard RW. An analysis of possible mechanisms of unexpected death occurring in hydatid disease (echinococcosis). *J Forensic Sci.* 2009;54(4):919-22. doi:10.1111/j.1556-4029.2009.01065.x PMID:19467137.
19. Salehi M, Soleimani A. Cardiac echinococcosis with negative serologies: a report of two cases. *Heart Lung Circ.* 2009;18(1):59-61. doi:10.1016/j.hlc.2007.08.006 PMID:18082448.