

# Qualitative Histological Analysis of Adrenal Cortex Following Application of Medroxyprogesterone Acetate

Elida Mitevska<sup>1</sup>, Mirko Spiroski<sup>2</sup>

<sup>1</sup>Institute of MEP Histology and Embryology, Faculty of Medicine, University "Ss Cyril and Methodius", Skopje, Republic of Macedonia; <sup>2</sup>Institute of Immunobiology and Human Genetics, Faculty of Medicine, University "Ss Cyril and Methodius", Skopje, Republic of Macedonia

## Abstract

**Citation:** Mitevska E, Spiroski M. Qualitative Histological Analysis of Adrenal Cortex Following Application of Medroxyprogesterone Acetate. *Maced J Med Sci.* 2010;3(2):XXX-XXX. doi:10.3889/MJMS.1957-5773.2010.0100.

**Key words:** adrenal cortex; histological analysis; medroxyprogesterone acetate; rats; in vivo.

**Correspondence:** Prof. Dr. Mirko Spiroski, Institute of Immunobiology and Human Genetics, Faculty of Medicine, University "Ss Kiril and Metodij", 1109 Skopje, PO Box 60, Republic of Macedonia. E-mail: mspiroski@yahoo.com

Received: 18-Mar-2010; Revised: 07-Apr-2010; Accepted: 12-Apr-2010; Online first: 23-Apr-2010

**Copyright:** © 2010 Mitevska E. This is an open-access article distributed under the terms of the Creative Commons Attribution License, which permits unrestricted use, distribution, and reproduction in any medium, provided the original author and source are credited.

**Competing Interests:** The authors have declared that no competing interests exist.

**Aim.** The aim of the investigation was to make a review of the morphological characteristics of the adrenal cortex following the application of high doses of medroxy-progesterone acetate (MPA).

**Material and Methods.** Total of 48 female Wistar rats were divided into four groups. Control group was given saline daily, intra-muscularly, and the other three groups MPA in doses of 7.5, 15.0 and 75.0 mg/kg bw during 30 days. Paraffin sections from adrenal glands were stained according the following methods: hematoxylin-eosin, Azan modified by Heidenhein, Van-Gieson, Kossa-Goldner, Masson and Florentin.

**Results.** Histological analysis demonstrated that MPA caused the following morphological changes in adrenal cortex: more intensive development of stroma; decrease of adrenal cortex thickness; disturbance of spacial organization of adrenocorticocytes in glomerular zone, fascicular zone and reticular zone; atrophic changes of adrenocorticocytes; disappearance of intermediary zone after application of 75.0 mg/kg bw MPA; appearance of microcysts in fascicular and reticular zones; decrease of cortical proliferate dimensions and accessory adrenal glands, disappearance of spongicytes from their structure and atrophic changes of glomerular cells; decrease of adrenal cortex vascularisation, necrotic changes localized subglomerularly and in fascicular zone of adrenal cortex.

**Conclusion.** MPA causes atrophic changes in adrenal cortex i.e., the decrease of its cell potential, a phenomenon suggesting that MPA possesses glucocorticoid characteristic.

## Introduction

Adrenal cortex secretes more than 30 different hormones called corticosteroids, which influence a great number of biochemical processes being crucial for maintenance of corporal physiological homeostasis. Adrenocorticocytes of various zones are specialized for synthesis of a special type of corticosteroids. All these hormones have their own chemical formula.

Medroxyprogesterone acetate (MPA) which generic name is 6 $\alpha$ -methyl-17-acetoxy pregn-4-ene-

3, 20 dione, is a synthetic progestation agent which, due to its steroid structure, shows a complex hormonal interference with a broad spectrum hormones: triiodothyronine (T-3), thyroxine (T-4), thyroid stimulating hormone (TSH), luteinizing hormone (LH), follicle stimulating hormone (FSH), prolactin (PRL), 17-beta estradiol, testosterone, aldosterone etc. [1-3]. Because MPA is a potent progestin, majority of investigators speaks for its affection on hypothalamo-pituitary-gonadal axis [4-11]. However, MPA as well as the other gestagens obtained from 17-alpha-hydroxy progesterone, has a

structural relation with glucocorticoid hormones because it is supposed that it has progestation beside the glucocorticoid activity.

Several authors studied MPA interference in glucoregulatory mechanisms of the organism. Eigenmann et al. [12] investigating glucose tolerance test and plasma insulin found that MPA caused elevation of mean glucose concentrations and the mean insulin levels. Selman et al. [13] also showed that after MPA application, insulin secretion was elevated in order to maintain the glucose homeostasis, while prolonged treatment with MPA resulted in glucose intolerance. Because glucocorticoid hormones have also great influence on glucose homeostasis, due to MPA glucocorticoid characteristics, its action on hypothalamo-pituitary-adrenal axis was studied. These investigators showed that MPA caused adrenal glands weight loss [6] and growth inhibition respectively [14], powerful decrease of serum cortisol and weak response of adrenal gland (after maximal stimulation with ACTH) [1,15-17]. When affecting the hypothalamo-pituitary-adrenal axis, adrenocortical component suppression was the most remarkable [13].

Because of all this, the aim of this paper is to determine the adrenocortical suppression from the morphological point of view, i.e. to survey the morphological characteristics of the cortical adrenal gland after the application of MPA.

## Material and Methods

The experiment included 48 intact, Wistar female rats divided into 4 groups, with 12 animals each. Control

group of rats administered 0.1 ml saline daily, intramuscularly, within 30 days. The other three groups of experimental animals administered MPA daily (Dugen forte, Inex Hemofarm, Vrsac, Serbia) in three different doses of: 7.5, 15.0 and 75.0 mg/kg bw, in volume of 0.1 ml, intramuscularly, within 30 days.

Animals had been sacrificed after 24 hours since the application of the last MPA dose, after ether narcosis. Adrenal glands were fixed in Bouin fixative. Routine method hematoxylin-eosine and trichrom methods: Azan, modified by Heidenhein, Van-Gieson, Kossa-Goldner, Masson and Florentin were used for staining the paraffin sections. Finally, qualitative histologic analysis was performed using the light microscopy.

## Results

### Adrenal gland stroma

In rat adrenal glands treated with MPA, the connective tissue and the gland stroma respectively, was strongly developed. Stronger connective tissue ingrowth was observed on some spots in connective capsula of the glomerular zone cells. Connective capsula thickness was seen extremely well (Fig. 1 a, b).

Also, a phenomenon having greater quantity of connective tissue among reticular zone adrenocorticocytes with dominance of collagenic fibres in relation to connective-cell elements was found. There was also thickening of the so-called internal connective capsula.

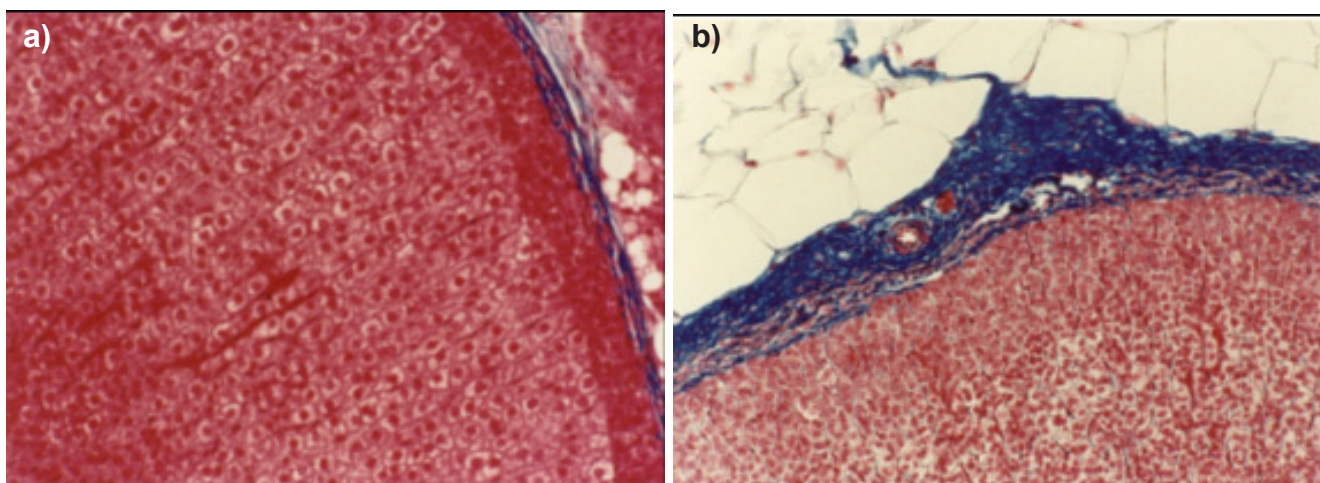


Figure 1: a) Control group: connective capsula on the adrenal gland surface, Azan, 10x 20; b) 75.0 mg/kg bw MPA; thickened connective capsula. Azan 10 x 20.

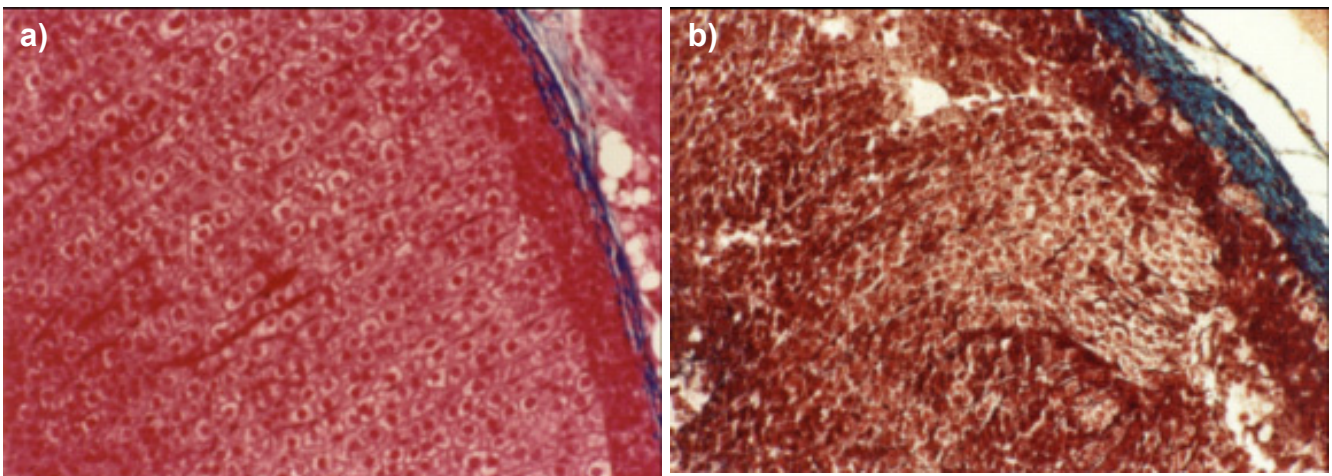


Figure 2: a) Control group: typical radial distribution of cell columns in fascicular zone. Azan, 10 x 20. b) 75.0 mg/kg bw MPA: disturbance of specific cytoarchitecture in fascicular zone. Masson, 10 x 20.

### *Adrenal cortex thickness*

Adrenal cortex thickness was notably decreased after the application of three differently high doses of MPA. This phenomenon mainly had been due to decrease of the fascicular and reticular zone thickness. The three zones could still be differentiated in the cortex although the boundary among them became vague. There was flattening of the boundary line between the fascicular zone and the reticular zone, so the boundary lost its typical wave-like shape.

### *Adrenocorticoyte spacial organization*

Disturbance of the specific adrenocorticoyte cytologic architecture was registered in all three zones.

Glomerular and arch-like structures being the main morphologic sign of the spacial cell organization in glomerular zone disappeared, and the cells were densely condensed and chaotically arranged. On the other side, the disturbance of the fascicular zone specific cytoarchitecture was characterized by a loss of radially placed cell columns, and the adrenocorticoytes were condensed and chaotically arranged. In minority of glands, there was disturbed spacial organization in a sense of change of direction in cell cordons, which, instead of radially, were placed in an oblique or parallel manner in relation to the gland surface (Fig. 2 a, b). Reticular zone gland cells were also densely condensed and their network distribution could not be clearly seen.

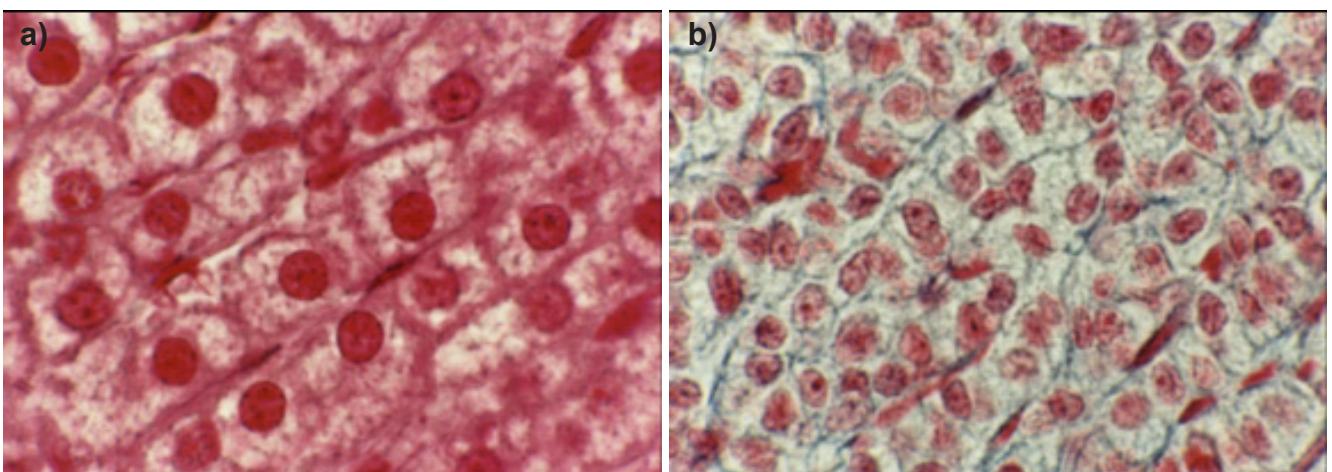


Figure 3: a) Control group: nuclei of spongiocytes with normal structure. Azan, 10 x 100. b) 75.0 mg/kg bw MPA: decreased, polymorphic and shrunken nuclei of spongiocytes. Azan, 10 x 100.

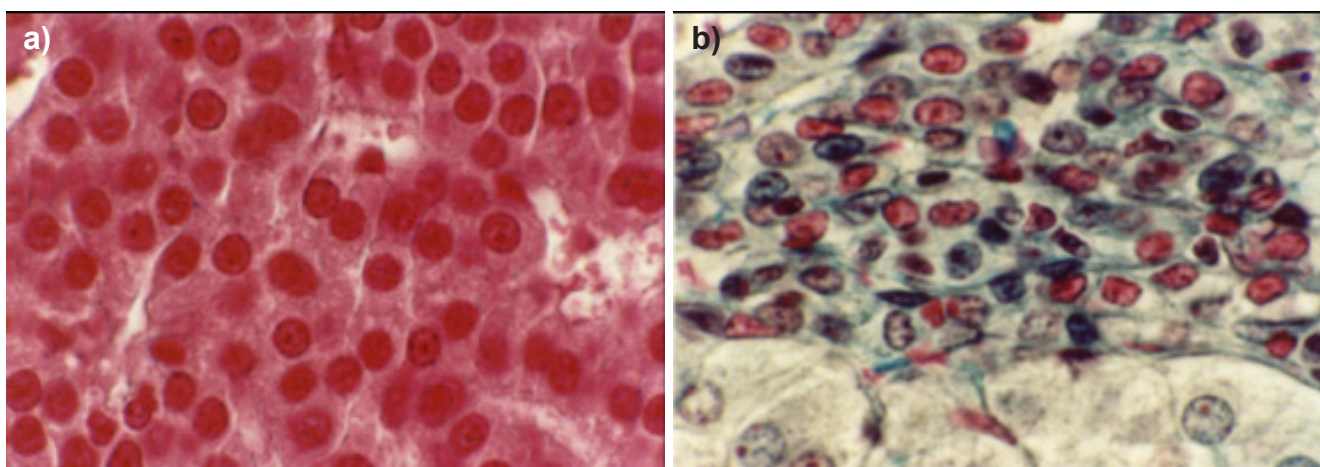


Figure 4: a) Control group: nuclei with normal cell structure from reticular zone cells. Azan, 10 x 100. b) 15.0 mg/kg bw MPA: polymorphic, polychromatic nuclei from reticular zone cells. Kossa-Goldner, 10 x 100.

#### *Adrenocorticyte morphological characteristics*

Adrenocorticytes from glomerular zone after treatment with 15.0 and 75.0 mg/kg MPA characterized with decrease in dimension. The nuclei were polymorph, polychromatic, and oftenly hyperchromatic. Fascicular zone adrenocorticytes showed atrophic changes after application of all three doses of MPA. They morphologically characterized with the so- called cellular condensation (cell shrinkage), chromatic aggregation (especially chromatin aggregation up to the nuclear membrane), incisures and invagination of the nuclear membrane, as well as decrease of cytoplasmatic quantity (Fig. 3 a, b), instead of disappearance of the commonly present vacuoles by what the characteristic spongiocyte sponge-like

appearance was lost. Reticular zone gland cells also showed diversity concerning the nuclear form, size and stain (Fig. 4 a, b), and their cytoplasm showed cytoplasmatic condensation because there was no clear difference between the light and dark cells.

#### *Intermediary zone persistence*

Intermediary zone persistence is a characteristic phenomenon arising when applied the MPA in doses of 7.5 and 15.0 mg/kg bw. When applying these doses, it was more often present and more clearly expressed than in the control animal groups. When applying the dose of 75.0 mg/kg bw MPA the intermediary zone could be rarely seen, and if present, it was poorly expressed.

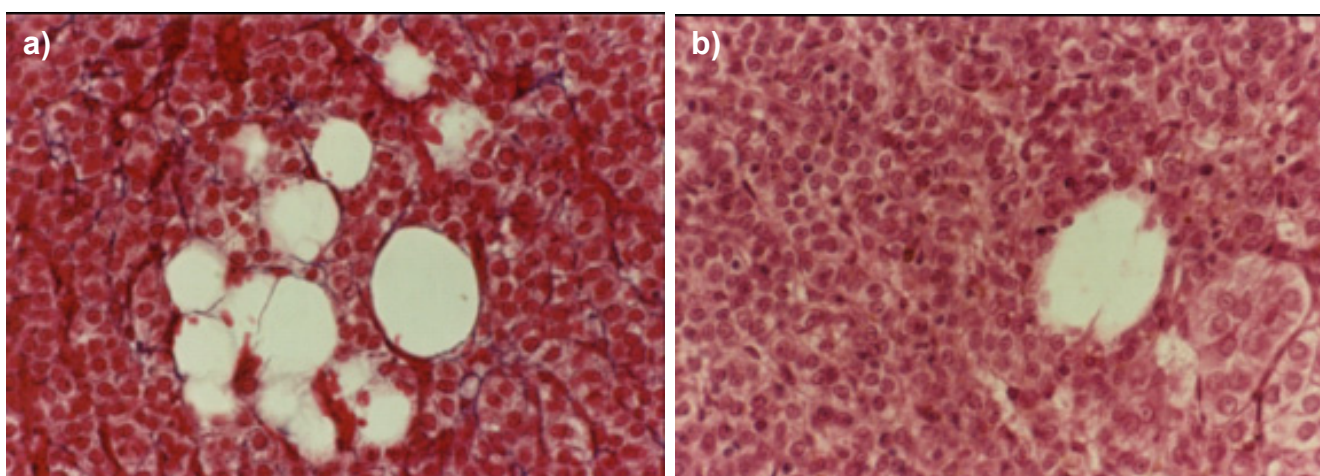


Figure 5: a) 7.5 mg/kg bw MPA: microcysts in fascicular zone. Azan, 10 x 40. b) 7.5 mg/kg bw MPA: microcyst in fascicular zone. Hematoxylin-eosin, 10 x 40.

### *Microcysts in cortical adrenal gland*

There were rare microcystic formations among the glomerular zone cells. Some of them were filled with eosinophilic stain material similar to colloid. Bigger microcysts were more frequently found among both the fascicular zone and reticular zone cells (Fig. 5 a, b).

adrenal glands in control rats were greater, and in their structure the cells from glomerular zone and fascicular zone participated the most frequently. But, after MPA treatment the cortical proliferates and the accessory adrenal glands had smaller dimensions, spongiocytes disappeared from their structure, and the glomerulosa-cells suffered atrophic changes (Fig. 6 a, b).

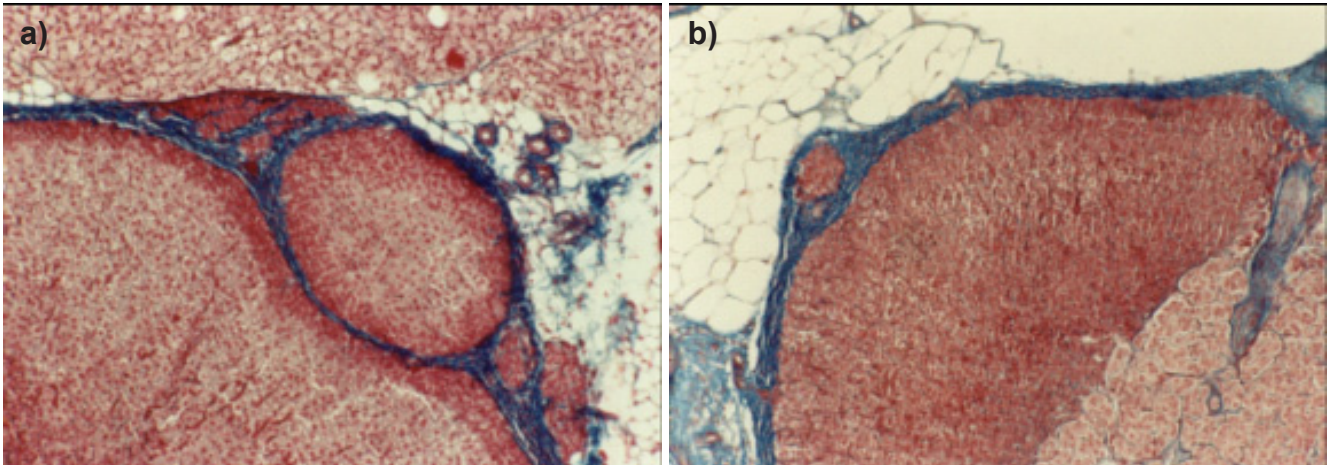


Figure 6: a) Control group: big cortical proliferate built by adrenocorticocytes in glomerular and fascicular zones. Azan, 10 x 10. b) 15.0 mg/kg bw MPA: small cortical proliferate built by adrenocorticocytes in glomerular zone. Azan, 10 x 10.

### *Cortical proliferates and accessory adrenal glands*

Cortical proliferates and accessory adrenal glands were found in both the controls and the rats treated with MPA. There was no great difference between the controls and the rats treated, in the frequency of this phenomenon. However, significant difference was found in size and histological structure. Cortical proliferates and accessory

### *Adrenal cortex vascularisation*

Vascular network histological structure showed remarkable reduction. Capillary blood vessels in glomerular zone were poorly expressed. Also, the sinusoidal capillary blood vessels in fascicular zone and reticular zone being especially well expressed and filled with blood in the control rat group, treated with MPA, were poorly expressed, emptied and collapsed. Loss of commonly radial

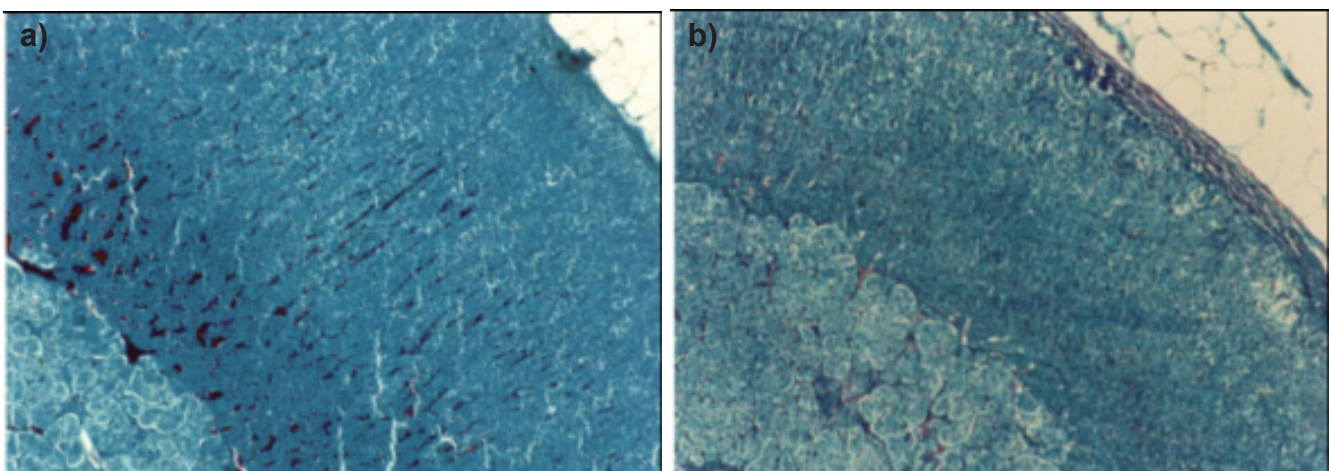


Figure 7: a) Control group: presence of clear sinusoidal blood capillaries. Florentin, 10 x 10. b) 7.5 mg/kg bw MPA: poorly delineated sinusoidal blood capillaries, Florentin, 10 x 10.

distribution in capillary network was also found in fascicular zone (fig. 7a, b).

### Necrotic alterations in adrenal gland

Following the eventual MPA histotoxic actions on adrenal gland, bleeding and destructive changes in the tissue were registered, being localized among the glomerular zone cells, subglomerularly, i.e. among both the intermediary zone cells and the fascicular zone cells (Fig. 8). Necrotic alterations affected the extended zones of adrenal cortex, and the tissue had characteristic signs for necrosis: destruction of cell membranes or complete cell lysis and their conversion into eosinophilic stained detritus mass. There was no inflammatory response which urgently followed necrosis. Necrosis of the adrenal cortex was more often noticed after application of 75.0 mg/kg bw MPA.

## Discussion

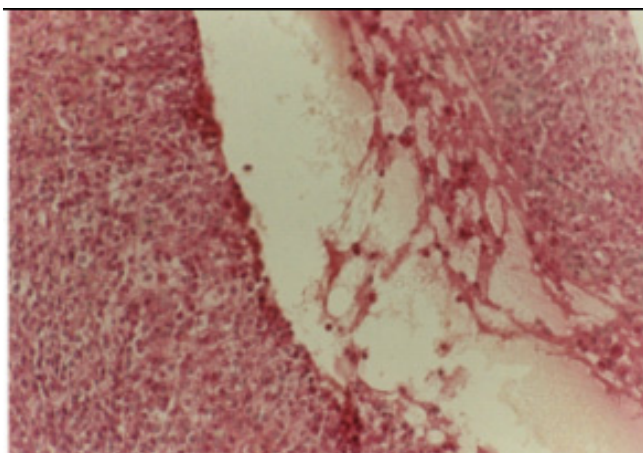


Figure 8: 7.5 mg/kg bw MPA: necrotic changes in external fascicular zone of adrenal cortex. Haematoxylin-eosin, 10 x 20.

Effect of three differently high doses of MPA on the adrenal cortex morphology was investigated in our trial. From the results obtained, it could be concluded that the adrenal cortex morphology significantly changes upon the influence of this progestin. Increase of adrenal gland stroma, adrenal cortex decrease, morphologic characteristics of adrenocorticocytes (chromatin aggregation and cytoplasmatic condensation), decrease of cortical proliferates dimensions and decreased vascularisation of the adrenal cortex are all typical morphologic indices which point to the adrenal cortex atrophic changes (Table 1). Atrophic changes and the decrease of the adrenal cortex cell potential respectively,

under the influence of MPA, is in line with a great number of morphological investigations which showed that under the influence of this progestin there is potent decrease of the adrenal gland cortisol secretion [13, 16, 18, 19].

In our investigation it was observed even stronger development of dense connective tissue (strongly developed connective capsula and strongly developed stroma in the reticular zone). These changes represent a morphological index for higher resistance of the connective tissue in relation to the endocrine tissue of adrenal cortex, i.e. the endocrine tissue is the main morphological substrate, against which the MPA expresses its activity. Connective tissue was especially potently developed in the reticular zone in which the number of the cell elements decreased and collagenic fibers dominated. This phenomenon indicates that the connective tissue cell elements show greater sensitivity of MPA in relation to collagenic fibers [20]. Cytological action of MPA on fibroblasts was also described by Andrada et al. [21].

Great contribution in confirmation that adrenal cortex was a specific substrate which potently connected progesteron steroids was given by Demura et al. [22]. They found that the guinea pig purified nuclear adrenal cortex contained a substance with progesteron connective ability, which most probably was of a protein origin. Connective ability of this nuclear protein was especially specific towards progestin steroids, among them the MPA as well. The proof for MPA high affinity towards this nuclear cortical adrenal protein was one evidence more, which proved the hypothesis that the adrenal gland was a target organ of MPA [7].

The morphological characteristics which have the adrenocorticocytes after the application of MPA go in favor of the hypothesis that physiological decrease of the adrenal cortex occur with gradual devastation of the adrenocorticocytes under the influence of MPA through

Table 1: Survey of morphologic characteristics of adrenal cortex after MPA application.

Morphologic substrate, localization	Changes after MPA application
1. Stroma	- strongly developed external and internal connective capsula - strongly developed interstitial connective tissue in reticular zone
2. Adrenal cortex thickness	- Decreased adrenal cortex thickness: 1. intensively decreased fascicular zone thickness 2. intensively decreased reticular zone thickness
3. Spacial organization of adrenocorticocytes	-chaotic distribution of adrenocorticocytes -alteration in direction of cells cordons
4. Adrenocorticocytes	-cellular condensation -nuclear alterations 1. polymorphism 2. polychromy 3. chromatic aggregation
5. Intermediary zone	-present after application of 7.5 and 15.0 mg/kg MPA -absent after application of 75.0 mg/kg bw MPA
6. Microcysts	Most often present in fascicular and reticular zones

individual cell death - apoptosis. The hypothesis for possible apoptotic changes of adrenal cortex under the influence of MPA has been mentioned for the first time by Fell et al. [23] because of the fact that the decrease of the number and the apoptosis of adrenocorticocytes always are accompanied by suppression of pituitary secretion of ACTH.

Results of our histologic analysis showed that the persistence of the intermediary zone was characteristic after the application of MPA in doses of 7.5 and 15.0 mg.kg bw. This phenomenon showed that beside the atrophic changes of the adrenocorticocytes, the adrenal gland still had ability to respond with partial complementing to the dead cells. Disappearance of intermediary zone after the application of the highest dose could be due to the MPA ability to make inhibition on cell mitogenesis [10, 24, 25], although there were authors who considered that MPA did not influence the mytotic phase of the cell cycle [26], while it realized its antiprolifertive activity binding with progesteron receptors.

Under the influence of high doses of MPA in adrenal cortex microcysts, which appearance most probably, had been due to accelerated apoptosis of adrenocorticocytes in fascicular and reticular zones were recorded.

Changes in size and histological structure of the cortical proliferates and accessory adrenal glands also indicated the atrophic changes and accelerated apoptosis of gland cells especially spongiocytes, i.e. impaired adrenal cortex function. Another morphological index, which pointed to decreased adrenal cortex function, has been the impaired vascularisation in it.

Remodeling of adrenal gland through adrenocorticocyte apoptotic processes has been suggested because of their cytologic changes caused by MPA [23]. However, in order to cause physiological cell death, plasma concentration of the drug used should run to some limit to which the cells could preserve their integrity and die in a rapid but still programmed way. In favor of this opinion comes the finding that the abrupt and rapid suppression of the adrenal cortex caused potent involuntary processes being very frequently followed by heamorrhagic and necrotic changes in adrenal cortex [27].

After the application of MPA, disturbance of the adrenocorticocyte spacial organization was noticeable which, most frequently, had been due to total occurrences in adrenal cortex: atrophy in the endocrine part of the adrenal cortex, stronger development of connective tissue,

decrease and collapse of sinusoid capillary blood vessels and bleeding and destructive changes of the adrenal cortex.

Progesterone and MPA have a similar but not identical effect on central and peripheral allopregnanolone and beta-END levels. Their association with an estrogenic compound does not interfere with the positive effects produced by estrogen on allopregnanolone and beta-END brain content [28]. It was published a case report of a patient with pedophilia who was treated over a 4-year period with medroxyprogesterone acetate (MPA) at a dose of 300 mg/day and as a consequence developed Cushing's Syndrome and adrenal insufficiency, for which he was treated and from which he recovered. He also reported a hypersexual reaction to his own past cessation of MPA. Gonadotropin-releasing hormone agonists, which have a more benign side-effect profile than MPA, are suggested as an alternative to MPA [29].

## Conclusion

Results of our investigation showed that MPA causes atrophic changes in adrenal cortex, decrease of its cell potential respectively, a phenomenon, which suggests that MPA has glycocorticoid feature and could be included into glycocorticoid agonists.

## References

1. Sadoff L, Lusk W. The effect of large doses of medroxyprogesterone acetate (MPA) on urinary estrogen levels and serum levels of cortisol T4 LH and testosterone in patients with advanced cancer. *Obstet Gynecol.* 1974;43(2):262-7. [PMID:4359078](#).
2. Sala G, Castegnaro E, Lenaz GR, Martoni A, Piana E, Pannuti F. Hormone interference in metastatic breast cancer patients treated with medroxyprogesterone acetate at massive doses: preliminary results. *IRCS J Med Sci.* 1978;6(4):129. [PMID:12312055](#).
3. Ichikawa J, Sumino H, Ichikawa S, Ozaki M. Different effects of transdermal and oral hormone replacement therapy on the renin-angiotensin system, plasma bradykinin level, and blood pressure of normotensive postmenopausal women. *Am J Hypertens.* 2006;19(7):744-9. [doi:10.1016/j.amjhyper.2005.10.006](#) [PMID:16814131](#).
4. Barbieri RL, Ryan KJ. Direct effects of medroxyprogesterone acetate (MPA) and megestrol acetate (MGA) on rat testicular steroidogenesis. *Acta Endocrinol (Copenh).* 1980;94(3):419-25. [PMID:6968496](#).

5. Novak E, Hendrix JW, Chen TT, Seckman CE, Royer GL, Pochi PE. Sebum production and plasma testosterone levels in man after high-dose medroxyprogesterone acetate treatment and androgen administration. *Acta Endocrinol (Copenh)*. 1980;95(2):265-70. [PMID:6449127](#).
6. Di Carlo F, Racca S, Conti G, Gallo E, Muccioli G, Sapino A, Bussolati G. Effects of long-term administration of high doses of medroxyprogesterone acetate on hormone receptors and target organs in the female rat. *J Endocrinol*. 1984;103(3):287-93. [doi:10.1677/joe.0.1030287](#) [PMID:6094695](#).
7. Prahalada S, Carroad E, Hendrickx AG. Embryotoxicity and maternal serum concentrations of medroxyprogesterone acetate (MPA) in baboons (*Papio cynocephalus*). *Contraception*. 1985;32(5):497-515. [doi:10.1016/0010-7824\(85\)90020-4](#) [PMID:2935368](#).
8. Pridjian G, Schmit V, Schreiber J. Medroxyprogesterone acetate: receptor binding and correlated effects on steroidogenesis in rat granulosa cells. *J Steroid Biochem*. 1987;26(3):313-9. [doi:10.1016/0022-4731\(87\)90095-1](#) [PMID:2953940](#).
9. Michael RP, Bonsall RW, Zumpe D. Medroxyprogesterone acetate and the nuclear uptake of testosterone and its metabolites by brain, pituitary gland and genital tract in male cynomolgus monkeys. *J Steroid Biochem Mol Biol*. 1991;38(1):49-57. [doi:10.1016/0960-0760\(91\)90400-Y](#) [PMID:1825470](#).
10. Surrey ES, Halme J. Direct effects of medroxyprogesterone acetate, danazol, and leuprolide acetate on endometrial stromal cell proliferation in vitro. *Fertil Steril*. 1992;58(2):273-8. [PMID:1386030](#).
11. Svensson LO, Johnson SH, Olsson SE. Plasma concentrations of medroxyprogesterone acetate, estradiol and estrone following oral administration of Klimaxil, Trisequence/Provera and Divina. A randomized, single-blind, triple cross-over bioavailability study in menopausal women. *Maturitas*. 1994;18(3):229-38. [doi:10.1016/0378-5122\(94\)90129-5](#) [PMID:8015506](#).
12. Eigenmann JE, Rijnberk A. Influence of medroxyprogesterone acetate (Provera) on plasma growth hormone levels and on carbohydrate metabolism. I. Studies in the ovariectomized bitch. *Acta Endocrinol (Copenh)*. 1981;98(4):599-602. [PMID:6458192](#).
13. Selman PJ, Mol JA, Rutteman GR, Rijnberk A. Progestin treatment in the dog. I. Effects on growth hormone, insulin-like growth factor I and glucose homeostasis. *Eur J Endocrinol*. 1994;131(4):413-21. [doi:10.1530/eje.0.1310413](#) [PMID:7921231](#).
14. Zieger G, Zieger W, Kubatsch B. Effect and duration of gestagen influence on adrenal cortex and ovary. A morphological study in the Syrian golden hamster. *Pathol Res Pract*. 1982;173(3):202-17. [PMID:7122317](#).
15. Hellman L, Yoshida K, Zumoff B, Levin J, Kream J, Fukushima DK. The effect of medroxyprogesterone acetate on the pituitary-adrenal axis. *J Clin Endocrinol Metab*. 1976;42(5):912-7. [doi:10.1210/jcem-42-5-912](#) [PMID:178684](#).
16. Blossey HC, Wander HE, Koebberling J, Nagel GA. Pharmacokinetic and pharmacodynamic basis for the treatment of metastatic breast cancer with high-dose medroxyprogesterone acetate. *Cancer*. 1984;54(6 Suppl):1208-15. [doi:10.1002/1097-0142\(19840915\)54:1+<1208::AID-CNCR2820541319>3.0.CO;2-K](#) [PMID:6088020](#).
17. van Veelen H, Willemse PH, Sleijfer DT, van der Ploeg E, Sluiter WJ, Doorenbos H. Mechanism of adrenal suppression by high-dose medroxyprogesterone acetate in breast cancer patients. *Cancer Chemother Pharmacol*. 1985;15(2):167-70. [PMID:3160504](#).
18. Van Veelen H, Houwerzijl J, Roding TJ, Tjabbes T, Vermeer RJ, Sleijfer DT, Pratt JJ, Willemse PH. Oral high-dose medroxyprogesterone acetate causes adrenal suppression in patients with breast cancer. *Eur J Cancer Clin Oncol*. 1982;18(10):1035-6. [doi:10.1016/0277-5379\(82\)90253-X](#) [PMID:6297915](#).
19. Papaleo C, Carella C, Zito GA, Figlia A, Capuano F, Amato G. ACTH and cortisol plasma levels in cancer patients treated with medroxyprogesterone acetate at high dosages. *Chimioterapia*. 1984;3(4):220-2. [PMID:6099752](#).
20. Mitevskaja E, Spiroski M. Histological characteristics of mesenteric lymph nodes after application of medroxyprogesterone acetate. *Maked Med Pregled*. 1998;52:3-7.
21. Comini Andrada E, Hoschoian JC, Anton E, Lanari A. Growth inhibition of fibroblasts by progesterone and medroxyprogesterone in vitro. *Int Arch Allergy Appl Immunol*. 1985;76(2):97-100. [doi:10.1159/000233673](#) [PMID:3967946](#).
22. Demura T, Driscoll WJ, Strott CA. Nuclear progesterone-binding protein in the guinea pig adrenal cortex: distinction from the classical progesterone receptor. *Endocrinology*. 1989;124(5):2200-7. [doi:10.1210/endo-124-5-2200](#) [PMID:2707153](#).
23. Fell BF, Campbell RM, Dinsdale D. Adrenocortical involution in rats during oestrus synchronisation with medroxyprogesterone. *Res Vet Sci*. 1977;22(3):316-23. [PMID:560035](#).
24. Staples LD, Heap RB, Brown D, Marrs RW. Structural requirements for steroid inhibition of sheep lymphocyte mitogenesis in vitro. *Steroids*. 1984;44(5):419-33. [doi:10.1016/S0039-128X\(84\)80002-1](#) [PMID:6544531](#).
25. Huber H, Husslein P, Michalica W, Wagenbichler P.

Radiosensitizing effect of medroxyprogesterone acetate on endometrial cancer cells in vitro. *Cancer*. 1984;54(6):999-1001. doi:10.1002/1097-0142(19840915)54:6<999::AID-CNCR2820540610>3.0.CO;2-Q PMID:6467144.

26. Classen S, Possinger K, Pelka-Fleischer R, Wilmanns W. Effect of onapristone and medroxyprogesterone acetate on the proliferation and hormone receptor concentration of human breast cancer cells. *J Steroid Biochem Mol Biol*. 1993;45(4):315-9. doi:10.1016/0960-0760(93)90348-Z PMID:8499339.

27. Mitevaska E, Spiroski M, Gerasimovska Z, Kakaseva L, Kalamaras A. Necrotic changes in the adrenal cortex provoked by high doses of medroxy-progesterone acetate.

*Maked Med Pregled*. 1997; 51:91-96.

28. Bernardi F, Pluchino N, Pieri M, Begliuomini S, Lenzi E, Puccetti S, Casarosa E, Luisi M, Genazzani AR. Progesterone and medroxyprogesterone acetate effects on central and peripheral allopregnanolone and beta-endorphin levels. *Neuroendocrinology*. 2006;83(5-6):348-59. doi:10.1159/000095400 PMID:16931878.

29. Krueger RB, Hembree W, Hill M. Prescription of medroxyprogesterone acetate to a patient with pedophilia, resulting in Cushing's syndrome and adrenal insufficiency. *Sex Abuse*. 2006;18(2):227-8. doi:10.1177/107906320601800208 PMID:16868842.