

Telfairia Occidentalis, a Prophylactic Medicine for Alcohol's Damaging Effect on the Testis

Edidiong Akang, Ademola Oremosu, Olufunke Dosumu, Adedayo Ejiwunmi

Department of Anatomy, College of Medicine, University of Lagos, P.M.B. 12003, Lagos, Nigeria

Abstract

Citation: Akang E, Oremosu A, Dosumu O, Ejiwunmi A. *Telfairia Occidentalis*, a Prophylactic Medicine for Alcohol'S Damaging Effect on the Testis. Maced J Med Sci. <http://dx.doi.org/10.3889/MJMS.1957-5773.2011.0198>.

Key words: Infertility; Ethanol; Serum testosterone; Luteinizing hormone; seminiferous epithelium; sperm count; sperm motility.

Correspondence: Mr. Edidiong Nnamso Akang, Department of Anatomy, College of Medicine, University of Lagos, P.M.B. 12003, Lagos, Nigeria. Phone: +2348065299278. E-Mail: eltyeddy@yahoo.com

Received: 11-May-2011; Revised: 28-Oct-2011; Accepted: 29-Oct-2011; Online first: 29-Nov-2011

Copyright: © 2011 Akang E. This is an open access article distributed under the terms of the Creative Commons Attribution License, which permits unrestricted use, distribution, and reproduction in any medium, provided the original author and source are credited.

Competing Interests: The author have declared that no competing interests exist.

Background: Concerns have been expressed about rising cases of male infertility. Studies have shown that alcohol impairs sexual performance and desire in men. It also affects sperm count lowering it and contributing to fertility problems.

Aim: This study investigated the role of *Telfairia occidentalis* in the protection of the testis against alcohol induced damage.

Material and Methods: 30 male Sprague-Dawley rats were divided into five groups of 6 each. They were administered distilled water, 30% v/v of ethanol at 2g/kg body weight, 200 mg/kg, 400 mg/kg and 600 mg/kg of *Telfairia occidentalis*, for 8 weeks after which their blood samples were collected for hormonal assay. The testis and cauda epididymis were also excised for histology and semen analysis.

Results: Alcohol depleted the germinal epithelium of the testis but animals that received *Telfairia occidentalis* showed a better germinal epithelial lining and a significant increase in semen parameters and hormone levels.

Conclusion: *Telfairia occidentalis* demonstrated a prophylactic effect on alcohol induced testicular damage and has improved semen quality. In addition, it also improved serum testosterone and luteinizing hormone levels.

Introduction

'Infertility is the inability of a sexually active, non-contracepting couple to achieve pregnancy in one year' [1]. It has been reported that about 25% of couples fail to achieve conception within 1 year, 15% seek medical treatment for infertility and less than 5% remain unwillingly childless [2].

Infertility affects both men and women. Literature suggests that disorders in males and females account for an equal proportion of infertility [1]. Concerns have been expressed about rising cases of male infertility [3].

This can be as a result of congenital and acquired urogenital abnormalities, infections of the genital tract, increased scrotal temperature (varicocele), endocrine disturbances, genetic abnormalities and immunological factors [4].

Studies have shown that alcohol impairs sexual performance and desire. It also affects sperm count lowering it and contributing to fertility problems [5, 6]. Studies on human beings have even shown that alcohol intoxication will at least temporarily reduce sperm count [7, 8]. In addition, there is evidence suggesting that long term use of alcohol will lead to more permanent damage,

including a permanent reduction in sperm count [9,10]. Van-Thiel [9] reports that alcohol atrophies the cytoplasmic mass of Leydig cells responsible for the secretion of the male sex hormone testosterone. Wright et al. [10] reports low doses of alcohol to cause a 44% reduction in testosterone levels.

Researchers have shown that when testosterone is decreased, Luteinizing hormone [LH] levels do not increase but sometimes decrease [7, 11]. Alcohol has also been reported to decrease the functioning of luteinizing hormone releasing hormone (LHRH) receptors, resulting in diminished LH release. Researchers have also reported that alcohol impairs the function of protein kinase C, a key enzyme in LH production. Alcohol also impairs steps critical to LH synthesis and secretion [7]. This affects sperm maturation which depends on the level of testosterone available [12]. Alcohol has been demonstrated to reduce synthesis of luteinizing hormone by its effect on the pituitary-gonadonal axis [9]. Also, studies have shown that alcohol causes most of its damage on the male reproductive system by inducing oxidative stress caused by abundance of free radicals [7].

Telfairia occidentalis commonly known as fluted pumpkin has the following chemical composition and functional properties: crude protein ($17.50 \pm 0.12\%$), carbohydrate ($17.96 \pm 0.35\%$), ash ($5.67 \pm 0.10\%$) and high percentage of crude fat ($42.17 \pm 0.27\%$) but low moisture content ($6.67 \pm 0.01\%$) [13]. Mineral composition revealed that the seed flour contains mostly potassium (1824 mg/100 g wet sample) followed by magnesium (535 mg/100 g wet sample) and sodium (280 mg/100 g wet sample) phosphorus (21000 $\mu\text{g/g}$), calcium (280 $\mu\text{g/g}$), iron (69 $\mu\text{g/g}$) and manganese (1.80 $\mu\text{g/g}$). The physicochemical analysis of the oil revealed an acid value of 3.56 ± 0.45 , saponification value of 188.24 ± 2.12 , iodine value of 78.26 ± 1.24 , free fatty acid 4.50 ± 0.15 , refractive index of 1.471 and tannins [14,15]. Fatty acids were detected in the oil. The unsaturated fatty acids were composed mainly of oleic (61.83%) and linoleic (16.44%) while the saturated fatty acids mainly of palmitic acid (21.20%). It can be considered as a good protein ingredient since it has a low gelation capacity of 14% (w/v), foaming capacity $12.8 \pm 1.10\%$, water and oil absorption capacities of $90.2 \pm 0.2\%$ and $183.4 \pm 2.5\%$, respectively [13]. The seed proteins have minimum solubility at pH 5.0 and is also rich in antioxidants like vitamin C and vitamin A [16].

Telfairia occidentalis leaves have been reported by Nwangwa et al. [17] to attenuate the testicular damage

induced by quinine. It was also found to reduce lipid peroxidation there by improving spermatogenesis [18]. This however disagrees with the findings of Oyeyemi et al. [19], who reported that *Telfairia occidentalis* leaves have a destructive effect on the testis. The aqueous extract of *Telfairia occidentalis* has been shown to be hepatoprotective against garlic-induced oxidative stress [20]. The administration of *Telfairia occidentalis* seed oil decreased plasma cholesterol levels, arteriosclerosis and other degenerative changes in several organs including the heart, liver and kidney [21]. In an earlier study, administration of *Telfairia occidentalis* increased sperm count in Sprague-Dawley rats [22].

This study is therefore designed to investigate the protective ability of *Telfairia occidentalis* seed oil over alcohol induced testicular damage.

Material and Methods

Extract preparation

Healthy fruits of *Telfairia occidentalis* (fluted pumpkin) were obtained from Mushin market, Lagos, Nigeria during the month of June, 2009. It was authenticated in Lagos University herbarium (Voucher no - LUH 2763), University of Lagos, Lagos. The naked seeds were dried in an oven in the laboratory at 30°C for one week. The seeds were blended to a fine powder using Maurine electric blender. The powder was preserved for extraction of the oil samples. The oil extract of the plant samples was obtained using petroleum ether in continuous extraction in a Soxhlet reflux apparatus [23, 24]. At the completion of extraction, the petroleum ether was completely evaporated using a rotary evaporator at 35°C (Heidolph Laborota 4010 digital). The concentrated oil was the desired sample.

Administration of alcohol & extract

The animals received a daily administration of 30% v/v of alcohol at a dose of 2 g/kg body weight via oral ingestion while *Telfairia occidentalis* seed oil was administered intraperitoneally at 3 different doses: 200 mg/kg, 400 mg/kg and 600 mg/kg body weight daily.

The experimental animals

30 male Sprague-Dawley rats weighing 170-200 g (12-13 weeks old) were randomly selected from the Laboratory Animal Center of the College of Medicine, University of Lagos. The rats were fed on standard diet (Bendel Feed and Flour Mills Ltd), water was given ad

libitum and maintained under standard conditions. The animal room was well ventilated with a temperature range of 25 - 27°C under day/night 12-12 h photoperiodicity. The rats were grouped into five groups (6 rats each) A, B, C, D and E. The use of the animals was approved by the Experimental Ethics Committee on Animals Use of College of Medicine, University of Lagos, Nigeria.

Experimental procedure

Group A (control) received distilled water, Group B received 30% v/v of ethanol at 2 g/kg body weight while groups C, D and E received 30% v/v of ethanol at 2 g/kg body weight with 200 mg/kg, 400 mg/kg and 600 mg/kg bw of *Telfairia occidentalis* respectively for 8 weeks with ethanol administered once every other day while *Telfairia occidentalis* was administered once daily (6 days/week). At the end of administration, blood was collected through the medial canthus of the eye into plain sample bottles and centrifuged for 5000 rpm for 10 minutes to obtain clear sera for hormonal assay. The rats were sacrificed by cervical dislocation and placed on dorsal recumbence. The testicles were surgically removed through a lower abdominal incision. It was freed of fats, weighed and histologically examined. The epididymis was trimmed off the testis and semen sample was collected from the cauda epididymis.

Routine histological preparation

The histology of the testes was done by modification of method described by Kayode et al. [25]. The organs were harvested and fixed in 10% buffered formalin [26, 27] for 24 hours after which it was transferred to 70% alcohol for dehydration. The tissues were passed through 90% and absolute alcohol and xylene for different durations before they were transferred into two changes of molten paraffin wax for 1 hour each in an oven at 65 °C for infiltration. They were subsequently embedded and serial sections cut using rotary microtome at 5 microns. The tissues were picked up with albuminised slides and allowed to dry on hot plate for 2 min. The slides were dewaxed with xylene and passed through absolute alcohol (2 changes); 70% alcohol, 50% alcohol and then to water for 5 min. The slides were then stained with haematoxylin and eosin. The slides were mounted in Canada balsam. Photomicrographs were at magnifications of $\times 100$.

Testicular weight

Weights of testes were taken before immersion

in formalin using Scout (tm) Pro SPU 2001, electronic weighing balance, manufactured by Ohaus Corporation, Pine Brook, NJ USA.

Hormonal assay

The blood specimens from the subjects were collected into plain sample bottles and were immediately centrifuged to separate the sera from the cells. The sera were labelled and analysed. Testosterone and luteinizing hormones were assayed using the enzyme immunoassay methods of DIAGNOSTIC AUTOMATION, INC (2008) [28].

Sperm Motility Analysis

The slides on which the sperm cells were counted were warmed to 37°C until the time of the analysis. The analysis was carried out at room temperature using one epididymis of each rat. The percentage of sperm motility was calculated using the number of live sperm cells over the total number of sperm cells (both motile and non - motile), from two samples from one epididymis of each rat. All sperm cells that were not moving at all were considered to be non - motile, while the rest, which displayed some movement, were considered to be motile [29].

Sperm count

This was achieved using the new improved Neubauer's counting chamber (Heamatcytometer). The epididymal fluid from both epididymides was diluted with physiological solution by adding 0.9 ml to 0.1 ml of the crushed epididymides. The counting chamber was next charged with a cover slip until a rainbow picture was seen at the edges. This chamber was then filled with sperm fluid and placed under a binocular light microscope using an adjustable light source. The ruled part was then focused and the number of spermatozoa counted in five 16-celled squares. The total sperm cells were added, divided by two and multiplied by 10^6 and expressed as $(X) \times 10^6/\text{ml}$, where X is the total number of sperm cells in the five 16-celled square after dividing by two [30]

Statistics

The data obtained from all the groups were compiled and statistically analyzed and expressed as mean \pm standard deviation. Differences between groups were compared using one way ANOVA, with $p < 0.05$ considered significant. This was done using the SPSS software.

Results

Hormonal Assay

There was a significant decrease in serum testosterone levels with animals that received 8 weeks of ethanol (B) compared to those that received distilled water only (A) (Table 1). Animals that received 200 mg/kg of *Telfairia occidentalis* and ethanol for 8 weeks (C) showed a decrease in serum testosterone ($p>0.05$) but those that received 8 weeks of 600 mg/kg *Telfairia occidentalis* and ethanol (E) showed a significant decrease compared to control (A) $p<0.05$. The animals that received 200 mg/kg (C) showed an increase in serum testosterone but those that received 400 mg/kg (D) of *Telfairia occidentalis* with ethanol for 8 weeks showed a significant increase compared to the group that received 30% v/v of ethanol (B) $p<0.05$ (Table 1).

There was no significant difference in the LH of all experimental animals compared to control except the animals that received 8 weeks of ethanol (B) $p<0.05$. Groups that received 200 mg/kg, 400 mg/kg and 600 mg/kg of *Telfairia occidentalis* with ethanol for 8 weeks showed significant increases in LH when compared with those that received ethanol only (B) $p<0.05$ (Table 1).

Table 1: Effect of *Telfairia occidentalis* on serum testosterone and luteinizing hormones.

Groups	Drug administered	Testosterone (ng/ml)	Luteinizing hormone (ng/ml)
A (control)	Distilled water 8 wks	3.0 ± 1.9	3.3 ± 1.2
B	30% v/v ethanol, 8 wks	1.2 ± 0.2*	1.3 ± 0.3*
C	T.O. (200 mg/kg + ethanol) 8 wks	1.7 ± 0.3	2.4 ± 0.5**
D	T.O. (400 mg/kg + ethanol) 8 wks	2.6 ± 0.3**	2.9 ± 0.0**
E	T.O. (600 mg/kg + ethanol) 8 wks	1.4 ± 0.4*	2.0 ± 0.1**

T.O.- *Telfairia occidentalis*; Values are mean ± standard deviation, * $p<0.05$ vs. control group; ** $p<0.05$ vs. Group B.

Testicular weight

There was a significant increase in the group that received 400 mg/kg of *Telfairia occidentalis* and ethanol for 8 weeks (D), compared to those that received only ethanol (B) $p<0.05$. There was a non significant increase in the group that received 200 mg/kg of *Telfairia occidentalis* with ethanol and there was also a reduction in the group that received 600 mg/kg of *Telfairia occidentalis* and ethanol (E) compared to those that received ethanol (B).

When the experimental animals were compared to control (A), there was no statistically significant difference $p>0.05$ (Table 2).

Semen parameters

The animals that received 200 mg/kg and 400 mg/kg of *Telfairia occidentalis* and ethanol (C and D respectively) showed a significant increase in sperm motility compared to those that received just ethanol (B) $p<0.05$ (Table 2). Those that received 600 mg/kg of *Telfairia occidentalis* with ethanol (E) showed a non significant decrease in motility compared to those that received only ethanol (B) $p>0.05$ (Table 2).

Table 2: Effect of *Telfairia occidentalis* on sperm motility, sperm count, testicular weight.

Groups	Drug administered	Motility%	Sperm count (10^6 /ml)	Testicular wt (g)
A (control)	Distilled water 8 wks	55.8 ± 4.3	40.3 ± 9.5	0.9 ± 0.1
B	30% v/v ethanol 8 wks	42.3 ± 2.5	20.3 ± 4.1*	0.7 ± 0.2
C	T.O. (200 mg/kg + ethanol) 8 wks	60.0 ± 5.0**	24.3 ± 4.0*	0.8 ± 0.6
D	T.O. (400 mg/kg + ethanol) 8 wks	56.7 ± 2.9**	38.0 ± 7.5**	1.1 ± 0.1**
E	T.O. (600 mg/kg + ethanol) 8 wks	40.0 ± 5.0	18.3 ± 7.6*	0.7 ± 0.1

T.O = *Telfairia occidentalis*; Values are mean ± standard deviation, * $p<0.05$ vs. control group; ** $p<0.05$ vs. Group B.

Animals that received ethanol for 8 weeks (B) showed a significant decrease in sperm count compared to control (A) $p<0.05$ (Table 2). Also, those that received 200 mg/kg and 600 mg/kg (C and E) of *Telfairia occidentalis* and ethanol for 8 weeks showed a statistically significant decrease compared to control (A) but the animals that received 400 mg/kg of *Telfairia occidentalis* and ethanol showed statistically significant increase compared to those that received ethanol (B) $p<0.05$. At 200 mg/kg of *Telfairia occidentalis*, sperm count increased but decreased at 600 mg/kg $p>0.05$ (Table 2).

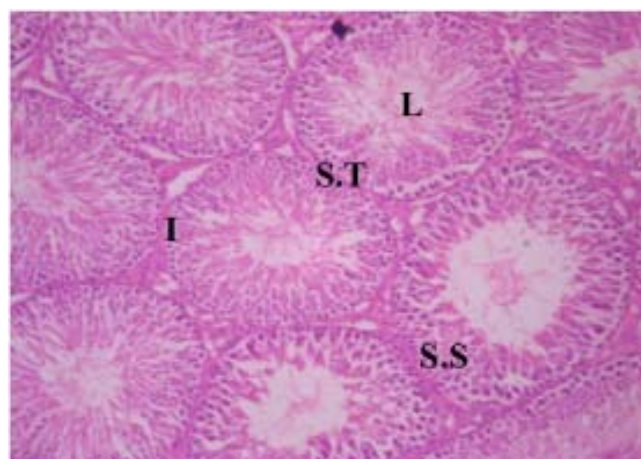


Figure 1: Section through the testis of group A (control) at magnification $\times 100$, showing interstitial cells of Leydig (I) with a well developed spermatogenic series (S.S) and mature spermatozoa in the lumen (L) of seminiferous tubule (S.T).

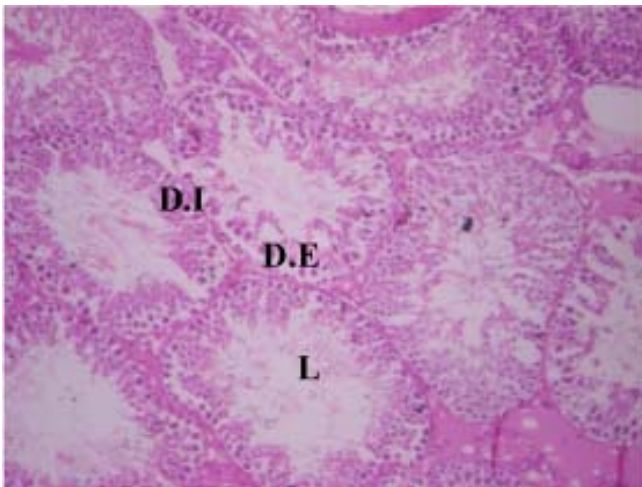


Figure 2: Section through the testis of group B (30% v/v of ethanol) at magnification $\times 100$, showing hypocellularity leading to an enlarged lumen (L), a distorted epithelium (D.E) and a distorted interstitium (D.I).

Testicular Histology

The testicular histology of control animals (group A) reflects a well arranged spermatogenic cell series with a normal interstitium (Figure 1). Animals that received 8 weeks of ethanol only (B) showed distortion in the seminiferous tubules and necrosis of the seminiferous epithelium (Figure 2). There was however an improvement in animals that received 200 mg/kg and 400 mg/kg of *Telfairia occidentalis*, with ethanol as depicted in Figure 3 and 4 respectively compared to those that received ethanol only (Figure 2). At 200 mg/kg of *Telfairia occidentalis*, the testis showed a normal interstitium and a normal seminiferous epithelium in most of the tubules (Figure 3). At 400 mg/kg of *Telfairia*

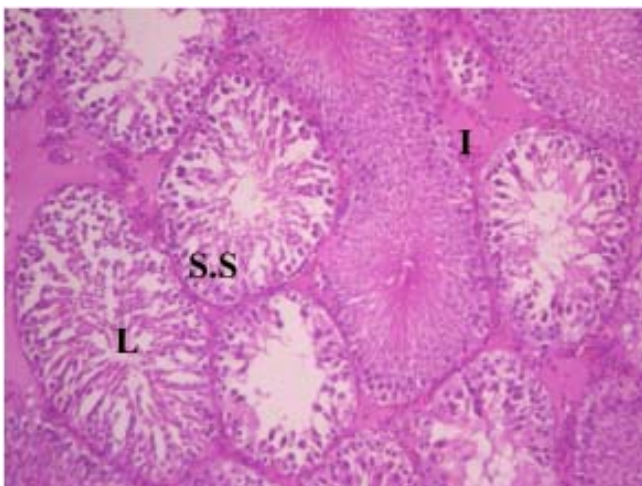


Figure 3: section of testis of group B (200 mg/kg bw of *Telfairia occidentalis*. with ethanol) at magnification $\times 100$, showing sperm cell in Lumen (L) slight distortion of spermatogenic cell series (S.S) and interstitial cells of Leydig (I) .

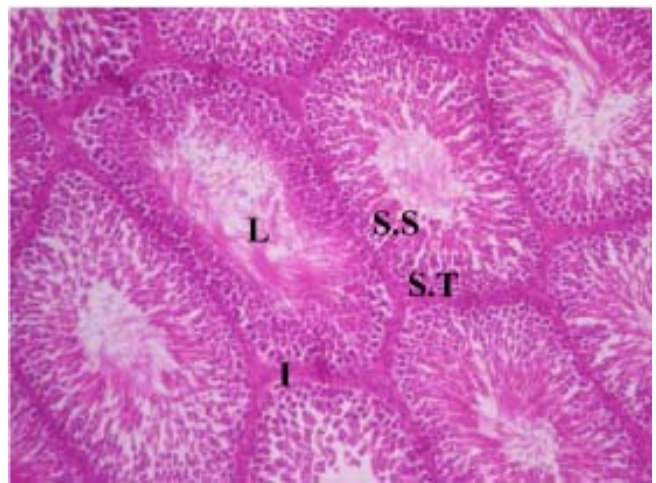


Figure 4: Section of testis of group C (400 mg/kg bw of *Telfairia occidentalis*. with ethanol) at magnification $\times 100$, showing a good spermatogenic cell series (S.S) with mature sperm cell in the lumen (L) and a well differentiated seminiferous tubule (S.T) with interstitial cells of Leydig in between them.

occidentalis, the testis showed a normal interstitium, normal seminiferous tubules and a well differentiated seminiferous epithelium (Figure 4) but at 600 mg/kg of *Telfairia occidentalis*, it showed a distorted seminiferous epithelium and lumen (Figure.5)

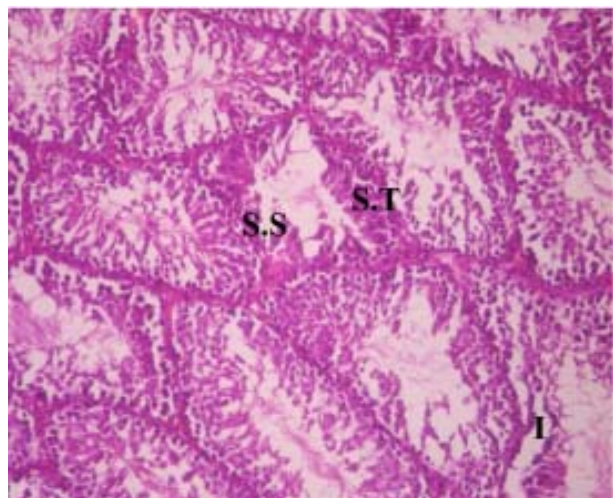


Figure 5: Section of testis of group D (600 mg/kg bw of *Telfairia occidentalis* with ethanol) at magnification $\times 100$, showing a distorted spermatogenic cell series (S.S), a distorted interstitium (I) and a reduced seminiferous tubule (S.T).

Discussion

From the present study, chronic administration of alcohol suppressed testosterone significantly with a concomitant decrease in luteinizing hormone levels. This suggests that alcohol affected the testosterone

feedback system and the hypothalamic cells which produce Luteinizing hormone releasing hormone (LHRH). Research with young (i.e., pubertal) male rats indicate that both acute and chronic alcohol exposure result in profound testosterone suppression accompanied by lower or normal luteinizing hormone (LH) and follicle stimulating hormone (FSH) levels, when elevated levels are expected [7, 31]. This suggests that the hypothalamic cells which produce LHRH do not function correctly when the feedback normally provided by testosterone is removed (i.e., when testosterone levels decrease). Thus, it appears that alcohol's damaging effects on reproduction are mediated at all three levels of the male reproductive unit: the hypothalamus, pituitary, and testes.

Spermatogenic cells occupy 95 percent of testicular volume. Therefore, failure of spermatogenesis may be characterized by testicular atrophy associated with oligospermia or azoospermia [10]. In this study, it was observed that suppressed testosterone levels showed simultaneous reduction in seminiferous epithelial growth and caused oligospermia and athenospermia on chronic administration of 30% v/v of ethanol. This is assumed to have led to testicular atrophy and hence the loss of testicular weight. This agrees with Willis [32], Anderson [33] and El-Ashmawy [34] who worked on 6%, 5% and 25% v/v of ethanol respectively and showed that it had adverse effects on sperm motility, sperm count, histological architecture and testicular weight. It however disagrees with Wright et al. [10]. According to him, decreased production of steroid sex hormones principally testosterone is characterized by loss of male secondary sex characteristics, impotence, diminished libido and many other symptoms but usually not a reduction in testicular size. It was also observed that *Telfairia occidentalis* ameliorated the deleterious effects of alcohol on the histology of the testis and sperm production. It proves to work optimally at a dose of 400 mg/kg. This finding supports the report by Nwangwu et al. [35], who reported that *Telfairia occidentalis* leaves had regenerative effects on the testes and improves sperm production. This could have been due to the presence of tocopherol (vitamin E), an antioxidant [14]. Antioxidants like vitamin A, C and E have been said to have good protective effects on the testis and hence improve male fertility [36,37]. It is believed that this antioxidant property must have protected the testis against lipid peroxidation caused by alcohol [34].

Linoleic acid, a polyunsaturated fatty acid present in this oil is known to increase membrane fluidity and allows for osmosis, intracellular and extracellular

gaseous exchange [38].

Though they are easily susceptible to lipid peroxidation, the presence of vitamin A prevents it [39]. Also, the presence of oleic acid, a monounsaturated fatty acid also reduces the susceptibility of the testis to lipid peroxidation [38,40]. This further explains the results obtained at 200 mg/kg and 400 mg/kg body weight.

This study further revealed that at higher doses (600 mg/kg), *Telfairia occidentalis* had adverse effects on testis and sperm parameters compared to the lower doses. This could be due to the presence of iron (Fe) in the oil. Iron, which though maintains proper cell function, could also be a pro-oxidant when administered at high doses [15, 41]. Therefore, when combined with alcohol, it had a deleterious effect and subjected the testis to more oxidative stress.

Tannins, though they are classified as antioxidants, at a high dose, they could become pro-oxidant, increasing lipid peroxidation [15, 42]. This explains for the drop in sperm count and motility including the decline in hormone levels at a dose of 600mg/kg body weight.

In conclusion, the present study demonstrates the potential benefits of Fluted pumpkin (*Telfairia occidentalis*) seed oil in ameliorating the deleterious effects of alcohol on the testes. These benefits can be attributed to the antioxidant potentials of *Telfairia occidentalis* which if developed can be added to the repertoire of antioxidant supplements available today. Even though, animal studies cannot be directly extrapolated to humans, the result from this present investigation gives a clue to the possible outcomes in humans with ethanol induced testicular damage.

References

1. Zegers-Hochschild F, Schwarze JE, Alam V. Infertility. International Encyclopedia of Public Health. 2008, 576-587.
2. Dohle G, Weidner W, Jungwirth A, Colpi G, Papp G, Hargreave T. EAU, Guidelines on male infertility. Eur Urol. 2005;48:703-711.
3. Kuku SF, Osegbe ND. Oligo/azoospermia in Nigeria. Arch Andrology. 1989;22:233-237.
4. Berkley M. Infertility: Men and Sperm Health. www.holisticonline.com. 2004, Last accessed, 29/05/2009
5. Bielawski DM, Abel EL. Acute treatment of paternal alcohol

- exposure produces malformations in offspring. *Alcohol*. 1997; 14:397-401.
6. Martinez M, Macera S, de Assis GF, Pinheiro PF, Almeida CC, Tirapelli LF, Martins OA, Mello-Junior W, Padovani CR, Martinez FF. Structural evaluation of the effects of chronic ethanol ingestion on the testis of *Calomys callosus*. *Tissue and Cell*. 2009;41:199-205.
 7. Emanuele M, Emanuele N. Alcohol and male reproductive system. National institute of Alcohol Abuse and Alcoholism. 2001;25:282-287.
 8. Gaur DS, Talekar MS, Pathak VP. Alcohol intake and cigarette smoking: Impact of two major lifestyle factors on male fertility. *IJPM*. 2010;53:35-40.
 9. Van Theil DH. Ethanol, its adverse effects upon the hypothalamic-pituitary gonadal axis. *J Lab Clin Med*. 1983;101: 21-33.
 10. Wright H, Gavaler J, Van thiel D. Effects of alcohol on male reproductive system. *Health Care Industry*. 1991;5:23-27.
 11. Gordon G, Altman K, Southern A, Rubin E, Lieber C. Effects of alcohol (ethanol) administration on sex hormone metabolism in normal men. *New Eng J Med*. 1976;295:793-796.
 12. Hafez B, Goff L, Hafez S. Recent advances in andrology research, physiotherapy and clinical application to fertility and infertility. *Arch Andrology*. 1997;39:173-195.
 13. Akintayo T. Chemical composition and physicochemical properties of fluted pumpkin (*Telfairia occidentalis*] seed and seed oils. *CODEN RISGAD*. 1997;74:13-15.
 14. Nkang A, Omokaro A, Egbe A. Variation of fatty acid proportion during dessication of *Telfairia occidentalis* seeds harvested at physiological and agronomic maturity. *Afr J Biotechnol*. 2003;2:33-39.
 15. Nworgu FC, Ekemezie AA, Ladele AO, Akinrolabu BM. Performance of broiler chickens served heat-treated fluted pumpkin (*Telfairia occidentalis*) leaves extract supplement. *Afr J Biotechnol*. 2007;6:818-825.
 16. Agatemor C. Fluted pumpkin (*Telfairia occidentalis* Hook F.) Seed: a Nutritional assessments. *Electronic Journal of Environmental, Agricultural and Food Chemistry*. 2007;6:17871793.
 17. Nwangwa EK, Mordi J, Ebeye OA, Ojeh AE. Testicular Regenerative Effects Induced by the Extract of *Telfairia Occidentalis* in Rats. *Caderno de Pesquisa, sñr Bio*. 2007;19: 27-35.
 18. Emeka EJ, Obidoa O. Some Biochemical, Haematological and Histological Responses to a Long Term Consumption of *Telfairia occidentalis*-Supplemented Diet in Rats. *Pak J Nutr*. 2009;8:1199-1203.
 19. Oyeyemi MO, Leigh OO, Ajala OO, Badejo AO, Emikpe BO. The effects of the aqueous extract of "ugu" (*Telfairia occidentalis*) leaves on the testis and spermatozoa Characteristics in the male albino rat. *Folia Veterinaria*. 2008;52:102-105.
 20. Olorunfemi AE, Arnold CI, Emmanue OI, Nkaima N, Akeem A. Hypoglycaemic activity of *Telfairia occidentalis* in rats. *J Pharm Biores*. 2005;2:36-42.
 21. Ajayi IA, Oderinde RA, Taiwo YO, Agbedana KO. Dietary effects on growth, plasma lipid and tissues of rats fed with non-conventional oil of *Telfairia occidentalis*. *J Sci Food Agric*. 2004;84:1715-1721.
 22. Akang EN, Oremosu AA, Dosumu OO, Noronha CC, Okanlawon AO. Effect of fluted pumpkin seed oil on testis and semen parameters. *Agric Biol J N Am*. 2010;1:697-703.
 23. Ojako OA, Nwanjo HU. Is *Vernonia amygdalina* hepatotoxic or hepatoprotective? Response from toxicity and Biochemical studies. *Afr J Biotechnol*. 2006;5:1648-1651.
 24. Reinhold BO. Evaluation of the chemical properties of plant extracts in Africa. *J Egypt Soc Horti*. 1992;16:497-498.
 25. Kayode O, Olusegun J, Adesanya A, Idowu O, Josiah S, Tolupe O. Effects of crude ethanolic extract of *Garcinia cambogia* on the reproductive system of male wistar rats (*Rattus novergicus*). *Afr J biotechnol*. 2007;6:1236-1238.
 26. Turk G, Atessahin A, Sonmez M, Ceribasi A, Yuce A. Improvement of cisplatin - induced injuries to sperm quality, the oxidant - antioxidant system, and the histologic structure of the rat testis by ellagic acid. *Fertility & Sterility*. 2008;89:1474-1481.
 27. Zaid TM, Khan AA. Effects of Longstanding Inguinal hernia on the microstructure of testis and spermatic tract sperm. *Biomedical Research*. 2011;22:1183-1186.
 28. Dosumu OO, Duru FIO, Osinubi AA, Oremosu AA, Noronha CC. Influence of Virgin Coconut oil (VCNO) on Oxidative stress, Serum testosterone and Gonadotropic hormones (FSH and LH) in chronic ethanol ingestion. *Agric Biol J N Am*. 2010;1:1126-1132.
 29. Yan J, Agresti M, Bruce T, Yan Y, Granlund A, Matloub H. Effects of cellular phone emissions on sperm motility in rats. *Fertility and Sterility*. 2007;88:957-964.
 30. Keel BA, Webster BW. *CRC Handbook of the Laboratory Diagnosis and Treatment of Infertility*. CRC Press, Boston. 1990: 45-47.
 31. Hadley ME. *Endocrinology*. 2nd Ed. Englewoods Cliff, NJ: Prentice Hall, 1988.
 32. Willis BR, Anderson RA Jr, Oswald C, Zaneveld LJ. Ethanol-induced male reproductive tract pathology as a function of ethanol dose and duration of exposure. *J Pharmacol Exp Ther*. 1983;225:470-478.

33. Anderson, RA, Willis, BR, Phillips, JF, Oswald, C, Zaneveld, LJ. Delayed pubertal development of the male reproductive tract associated with chronic ethanol ingestion. *Biochem Pharmacol.* 1987;36:2157-2167.
34. El-Ashmawy I, Selah A, Salama O. Effects of marjoram and Grape seed extract on ethanol toxicity in male rats. *Basic Clin Pharmacol Toxicol.* 2007;101:320-327.
35. Nwangwa EK, Mordi J, Ebeye OA, Ojeh AE. Testicular Regenerative Effects Induced by the Extract of *Telfairia Occidentalis* in Rats. *Caderno de Pesquisa, sñr Bio.* 2007;19: 27-35.
36. Amanvermez R, Serif D, Ozgur K, Tuncel Muhlise, A, Agar E. Alcohol-induced oxidative stress and reduction in oxidation by ascorbate /l-cys/l-met in the testis, ovary, kidney and lung of rat. *Advances in Therapy.* 2005;22: 548-558.
37. Glenville M. *The foundation of health: discover the fundamentals of a healthy life.* 2006, www.naturalHealthPractice/Ebooks_c79_cfm. Last accessed, 29/04/2010.
38. Lovejoy JC. The influence of dietary fats in insulin resistance . *Current Diabetes Reports.* 2002;2:435-440.
39. Patil RB, Vora SR, Pillai MM. Antioxidant effect of plant extracts on phospholipids levels in oxidatively stressed male reproductive organs in mice. *Iran J Reprod Med.* 2009;7:35-39.
40. Bourre J, Dumont O, Durand G. Dose-effect of dietary oleic acid: Oleic acid is conditionally essential for some organs. *Reprod Nutr Dev.* 2004;44:371-380.
41. Fattahi E, Parivar K, Jorsaraei SJ, Moghadamnia AA. The effects of diazinon on testosterone, FSH and LH levels and testicular tissue in mice. *Iran J Reprod Med.* 2009;7:59-64.
42. Taitzoglou A, Tsantarliotou M, Zervos I, Kouretas D, Kokolis N. Inhibition of human and ovine acrosomal enzymes by tannic acid in vitro. *Reproduction.* 2001;121:131-137.