

Ochratoxin A Toxic Effect on Rat Kidneys and the Potential Protective Effect of Ginseng: Histopathologic, Histochemical, and Image Analysis Morphometric Studies

Fatma A. Morsy, Amina A. Gamal el Din, Abdel Razik H. Farrag, Manal A. Badawi, Nermeen M. Shaffie

Pathology Department, National Research Centre, Cairo, Egypt

Abstract

Citation: Morsy FA, Gamal el Din AA, Farrag ARH, Badawi MA, Shaffie NM. Ochratoxin A Toxic Effect on Rat Kidneys and the Potential Protective Effect of Ginseng: Histopathologic, Histochemical, and Image Analysis Morphometric Studies. *Maced J Med Sci.* <http://dx.doi.org/10.3889/MJMS.1957-5773.2011.0195>.

Key words: Ochratoxin A; Rat Kidney; Ginseng; Histopathologic; Histochemical; Morphometric.

Correspondence: Abdel Razik H. Farrag. Pathology Department, National Research Centre, Dokki, Cairo, Egypt.
e-mail: abdelrazikfarrag@yahoo.co.uk

Received: 07-Jun-2011; Revised: 19-Sep-2011; Accepted: 20-Oct-2011; Online first: 07-Feb-2012

Copyright: © 2011 Morsy FA. This is an open access article distributed under the terms of the Creative Commons Attribution License, which permits unrestricted use, distribution, and reproduction in any medium, provided the original author and source are credited.

Competing Interests: The authors have declared that no competing interests exist.

Background: Ochratoxin A (OA), a secondary fungal metabolite, produced by *Aspergillus* and *Penicillium* strains and it is known to cause severe nephrotoxicity in animals and humans.

Aim: The effects on the histology and histochemistry of kidney of rats with ochratoxicosis and the potential protective role of ginseng against OA toxicity were investigated.

Subjects and Methods: Rats were divided into ten equal groups, eight rats of each; control, three groups of OA (0.85 mg/kg) were injected intraperitoneally for 2, 4, and 8 weeks, another three groups were treated with ginseng (20 mg/kg) plus OA for 2, 4, and 8 weeks. The remaining groups were injected with ginseng only. Histopathologic, histochemical, cytophotometric studies were used.

Results: OA showed histopathologic effects confirmed by image analysis morphometric studies on rat kidneys; as pyknotic nuclei, vacuolar and hydropic degeneration within tubular epithelial cells. Cell debris and hyaline casts within tubular lumina were encountered. In rats treated with ginseng and ochratoxin, improvements in the histological and histochemical features were noticed. Histochemical and cytophotometric analysis showed decrease in DNA, protein glycogen, and alkaline phosphatase contents in rats given OA, while ginseng caused a significant increase in these inclusions.

Conclusion: The ginseng was found to reduce the deleterious effects of OA that occurred in kidney.

Introduction

Ochratoxin A (OA) is a naturally occurring mycotoxin produced by *Aspergillus ochraceus* as well as other moulds found on a variety of food stuffs in many countries [1, 2]. Ochratoxin A has been detected worldwide in a wide range of food products, including cereals [3], poultry feeds [4], feedstuffs [5], green coffee beans [6], cocoa beans [7], wine grapes [8], dried vine fruits [9], peanuts [10] and beer [11].

It is a nephrotoxic, hepatotoxic, teratogenic,

carcinogenic agent to animals and possibly to humans [12]. It is one of the major mycotoxins that impairs growth and reproductive efficiency of animals [13]. Moreover, the involvement of OA in the development of different types of cancer such as renal adenocarcinoma, bladder carcinoma and testicular cancer has been reported in rats, mice and human [14].

The toxicity of OTA may be due to: (1) inhibition of ATP production (2) inhibition of protein synthesis (3) promotion of membrane lipid peroxidation [15].

Ginseng refers to several plants within *Panax* L., a genus of 12 species of slow-growing perennial plants with fleshy roots, in the family Araliaceae [16]. The commonly used ginseng principally includes *Panax ginseng* (Asian ginseng) and *Panax quinquefolius* (American ginseng) [17].

A recent nationwide survey for the use of natural products found that ginseng was the most common form of complimentary and alternative medicine therapy [18, 19]. It is induced in the reduction of blood lipids, immunostimulation, anti-inflammation, vasodilation, anti-stress, chemoprevention, and antioxidation [20-22]. It has the ability to stimulate ribonucleic acid and protein synthesis. This is considered as the basis of improvement of renal function [23].

Therefore, the aim of the present study was to verify whether the oral administration of ginseng might counteract the histopathological and histochemical effects of Ochratoxin-induced toxicity in kidney of rats.

Materials and Methods

Ochratoxin A

Crude OA was prepared and quantitatively determined according to Romero et al [24]. The acute oral LD₅₀ of OA for rats is 20-30 mg/kg [25].

Experimental design

Eighty male albino rats weighting 150-170 grams were included in this study.

Rats were divided into ten equal groups, each consisting of eight rats. Eight rats were used as control and received NaHCO₃ (1m/kg). The remaining rats were divided into 9 groups. The first group was injected intraperitoneally daily with ochratoxin at a dose of 1/10 LD₅₀ of OA dissolved in (NaHCO₃), for 2 weeks. The second group was injected daily with OA for 4 weeks and the third group was injected with OA for 8 weeks at dose equivalent to 1/10 LD₅₀. The fourth, fifth and sixth groups were given ginseng (20 mg/kg) intraperitoneally, 10 minutes before OA injection at daily dose of 0.85 mg/kg for 2,4 and 8 weeks respectively. The remaining groups were injected with ginseng alone following the same previous schedule of injection. Powder of ginseng root (aqueous extract) was obtained from IPECO Company, 10th Ramadan city, Egypt.

Histological and histochemical studies

The kidneys of different groups were removed and fixed in 10% saline formalin, 5mm thick paraffin sections were stained with haematoxylin and eosin for light microscope investigation. Sections of kidney were stained for DNA, mucopolysaccharides, protein and alkaline phosphates then were used for cytophotometric measurement. Feulgen reaction for DNA was applied for the histochemical demonstration of DNA. Mercury-bromophenol blue method was applied for the histochemical demonstration of the total proteins. The periodic acid Schiff's (PAS) technique was used to demonstrate the presence of polysaccharides in the kidney.

Cytophotometric measurements were obtained using Leica Qwin 500 Image Analyzer Computer System (England). The degree of reaction was chosen by the color detect menu and the areas of reactivity were masked by a red binary color and area was measured using an objective lens of magnification 40, and eye lens 10 the total magnification was 400. Ten fields were chosen in each specimen and the mean values were obtained.

Morphometry

The data were obtained using Leica Qwin 500 Image Analyzer Computer System (England). The image analyzer consisted of a colored video camera, colored monitor, hard disc of IBM personal computer connected to the microscope, and controlled by Leica Qwin 500 software. The glomeruli and damaged areas were measured. The areas of fifty-glomeruli/group were measured in the kidney of each group. The damaged areas were measured using an objective lens of magnification 10, and eye lens 10 the total magnification was 100. Ten fields were chosen in each specimen and the mean values were obtained.

Statistical analysis

Statistical analysis was determined by one-way ANOVA using GraphPad Prism, version 4. Results are presented as mean ± standard error. Significance of the results was evaluated by using the student *t*-test. Results with P < 0.05 are considered significant.

Results

Histopathological results

The normal histological structure of the kidney was observed in (Figure 1-A) .

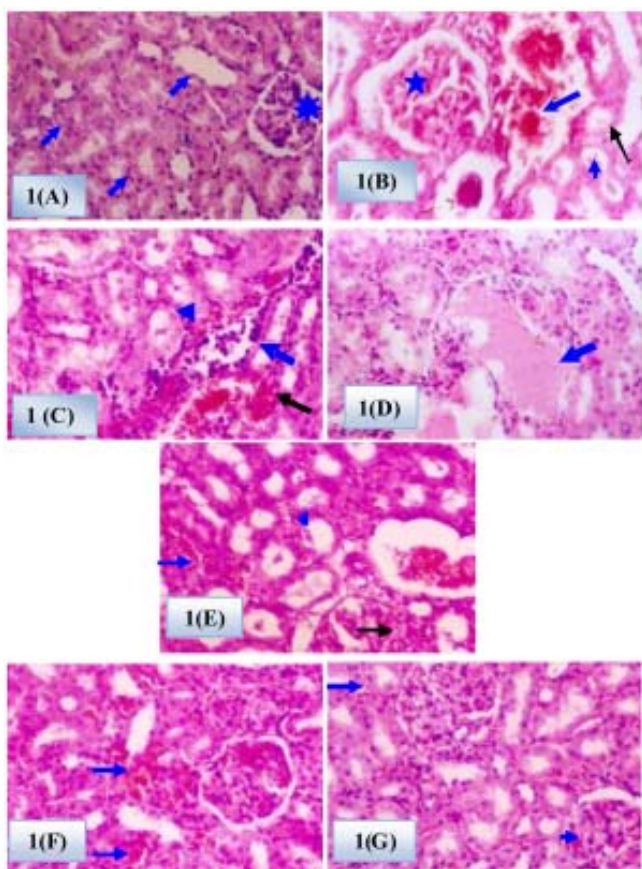


Figure 1: (H & E X200). A. Section of the kidney of control rat shows normal appearance of glomerulus (asterisk) and renal tubules (arrows). B. Section of the kidney of rat treated with OA for two weeks shows cell debris in the lumen of tubules (arrow), glomerular (asterisk), tubular cells (arrowhead) degeneration, and interstitium haemorrhage (arrow). C. Section of the kidney of rat treated with OA for four weeks showing mononuclear cellular infiltration (arrow) and haemorrhage in the interstitium (black arrow). Cell debris in the lumen of tubules (arrowhead) D. Section of the kidney of rat treated with OA for eight weeks showing hyaline casts (arrow). E. Section of the kidney of rat treated with ginseng and OA for two weeks shows vacuolar degeneration (black arrow), cell debris in lumen of tubules (arrowhead) and prominent internal hemorrhage (blue arrow). F. Section of the kidney of rat treated with ginseng and OA in combination for four weeks showing hemorrhage in the interstitial tissue (arrows). Section of the kidney of rat treated with ginseng and OA in combination for eight weeks shows hemorrhage in the interstitial tissue (arrow) and intraglomerular hemorrhage (arrowhead).

The kidney of animals treated with OA for two weeks showed tubular degeneration and cell debris in the lumen of tubules. Haemorrhagic areas in the interstitium and glomerular degeneration also appeared (Figure 1-B). In rats treated with OA for four weeks, kidney showed vacuolar degeneration and focal necrosis in tubular epithelial cells. Moreover, mononuclear cellular infiltration, haemorrhage in the interstitial tissue, cell debris in the lumen of tubules were noticed (Figure 1-C).

On the other hand, kidney of rats treated with OA for eight weeks showed hyaline casts and cell debris in the lumen of tubules, vacuolar degeneration, focal area of necrosis, karyolysis in tubular epithelial cells, glomerular degeneration and prominent internal hemorrhage (Figures 1- D). The treatment of rats with ginseng and ochratoxin in combination for two weeks showed that tubular and glomerular degeneration was diminished. Haemorrhagic areas were still present in the interstitium (Figure 1- E). In case of rats that treated with OA and ginseng for four and eight weeks, kidney showed few interstitial and intraglomerular hemorrhage. In

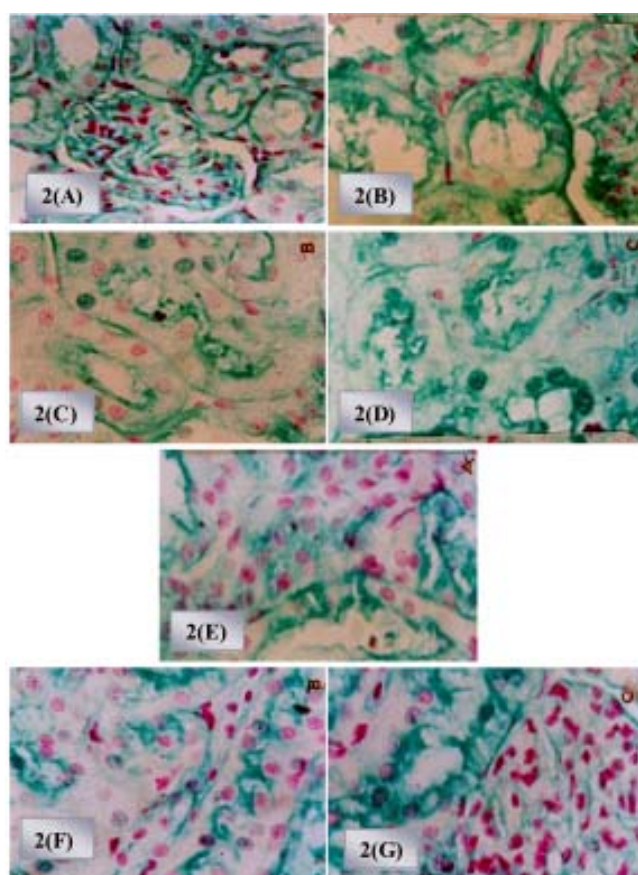


Figure 2: (Feulgen reaction x 400). A. Section of kidney of control rat shows normal distribution of DNA content in the nuclei of the renal tubules and mesangial cells of glomeruli. B. Section of kidney of rat treated with OA for two weeks shows a slight decrease in the DNA content. C. Section of kidney of rat treated with OA for four weeks shows a decrease in DNA. D. Section of kidney of rat treated with OA for eight weeks shows a marked decrease in the DNA content of the nuclei of the degenerated renal tubules. E. Section of kidney of rat treated with ginseng and OA for two weeks shows an increase in DNA content in comparison to toxin. F. Section of kidney of rat treated with ginseng and OA for four weeks shows an increase in DNA content in comparison to toxin. G. Section of kidney of rat treated with ginseng and OA for eight weeks shows that is nearly similar to that of the control rats.

comparison with rats treated with OTA only, a diminution of hyaline casts and vacuolar degeneration were observed (Figure 1- F, G).

Histochemical results

Figure (2-A) shows the normal distribution of DNA in the kidney of control rat.

DNA content in kidney cells of the rats injected with OA (Table 1) showed significant decrease ($P < 0.05$) as follows 22.22%, 34.21% and 40% after two, four and eight weeks respectively. Figures 2-B, C, D showed decrease in DNA distribution in kidneys of rats treated with OA only for two, four, and eight weeks.

Table 1: Effect of ochratoxin A (OA) (1/10 LD₅₀/kg b.w) and or ginseng (20 mg/kg b.wt) on DNA (ng/g), protein (ng/g), glycogen (mg/g) contents and alkaline phosphatase activity (mg/g) in kidney cells of male rats after two, four and eight weeks of intraperitoneal treatments.

		DNA	Protein	Glycogen	Alkaline phosphatase
2 weeks	Control	0.36 ± 0.01	0.42 ± 0.02	0.40 ± 0.01	0.29 ± 0.03
	Ginseng	0.57 ± 0.01*	0.67 ± 0.01*	0.40 ± 0.01	0.33 ± 0.01
	OA	0.28 ± 0.02*	0.37 ± 0.02	0.35 ± 0.01	0.31 ± 0.01
	OA+ Ginseng	0.32 ± 0.02	0.53 ± 0.01**	0.55 ± 0.01**	0.28 ± 0.003
4 weeks	Control	0.38 ± 0.01	0.43 ± 0.01	0.39 ± 0.001	0.30 ± 0.01
	Ginseng	0.64 ± 0.01	0.82 ± 0.03*	0.48 ± 0.003*	0.42 ± 0.04*
	OA	0.25 ± 0.01*	0.33 ± 0.01*	0.33 ± 0.01*	0.40 ± 0.003*
	OA+ Ginseng	0.42 ± 0.04**	0.73 ± 0.02**	0.56 ± 0.01**	0.38 ± 0.020**
8 weeks	Control	0.35 ± 0.01	0.42 ± 0.1	0.40 ± 0.01	0.30 ± 0.01
	Ginseng	0.70 ± 0.01*	0.88 ± 0.01*	0.86 ± 0.01*	0.61 ± 0.02*
	OA	0.21 ± 0.02*	0.22 ± 0.02**	0.25 ± 0.02*	0.71 ± 0.020*
	OA+ Ginseng	0.78 ± 0.02**	0.98 ± 0.01**	0.57 ± 0.01**	0.79 ± 0.001**

* Significant difference as compared with control ($P < 0.05$), ** Significant difference as compared with OA ($P < 0.05$).

Highly significant increase in DNA content ($P < 0.05$) was recorded in the case of rats treated with ginseng before ochratoxin injection especially after eight weeks by 122.85 (Table 1, Figure 5) as compared to control value. Figures 2- E, F, G showed an increase in DNA distribution in kidneys of rats treated with ginseng and OA only for two, four and eight weeks. In normal rat high protein inclusions in renal tubular cells were localized in the cytoplasm and lesser extent in their nuclei (Figure 3-A). Also the optical density values of protein content showed significant decrease ($P < 0.05$) (Table 1, Figure 5) in rats treated with OA only for two, four and eight weeks as compared with control one.

The percentage of decrease of protein content was 11.90%, 23.25%, and 47.61% at the three time intervals. Figures 3-B, C, D indicated low protein inclusions in renal tubular cells that were localized in the cytoplasm and their nuclei as compared with the control group. A significant increase in protein content ($P < 0.05$) was recorded in the case of rats given ginseng in

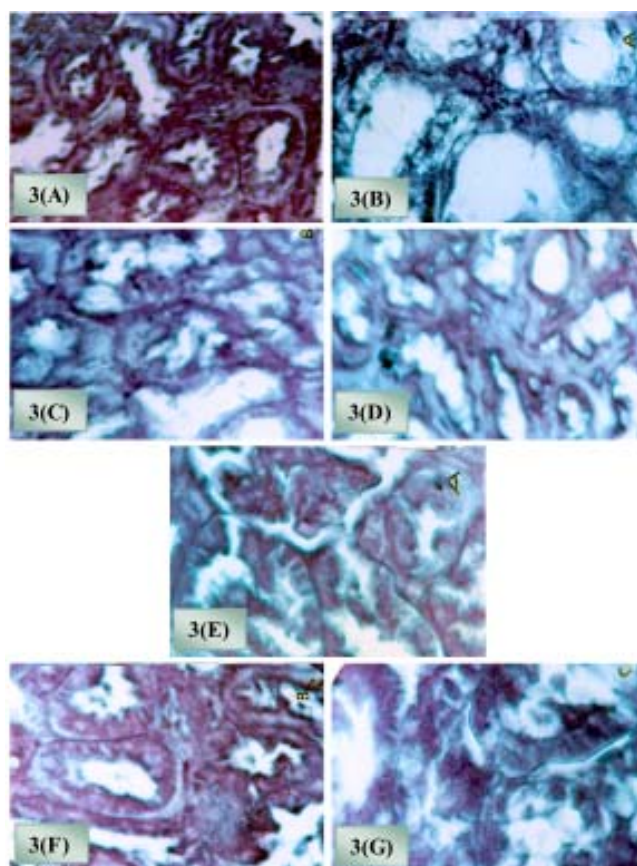


Figure 3: (Bromophenol blue stain x 400). A. Section of kidney of control rat showing normal distribution of protein in renal corpuscles and in the cells of the renal tubules. B. Section of the kidney of rat treated with OA for two weeks shows protein content. Notice that these inclusions are diminished and acquire pale stainability in some tubules. C, D. Sections of the kidney of rat treated with OA for four and eight weeks shows the distribution of the protein content. These inclusions display decrease in the cells of the renal tubules; many of cells appear almost unstained. E. Section of the kidney of rat treated with ginseng and OA in combination for two weeks showing an increase in protein content in comparison to toxin alone. F. Section of the kidney of rat treated with ginseng and OA in combination for two weeks shows an increase in protein content in comparison to toxin alone. G. Section of the kidney of rat treated with ginseng and OA in combination for two weeks shows an increase in protein content in comparison to toxin alone.

combination with ochratoxin by 26.19%, 69.76%, and 133.33% at different time of injections (Table 1, Figure 5). Figures 3- E, F, G showed an increase of protein inclusions in renal tubular cells that were localized in the cytoplasm and their nuclei in the group treated with ginseng and OA for two, four and eight weeks as compared with OA treated group.

The PAS +ve materials in the control group were mainly distributed at the brush border and basement membrane of the tubules (Figure 4-A).

Moreover, the glycogen content (Table 1, Figure

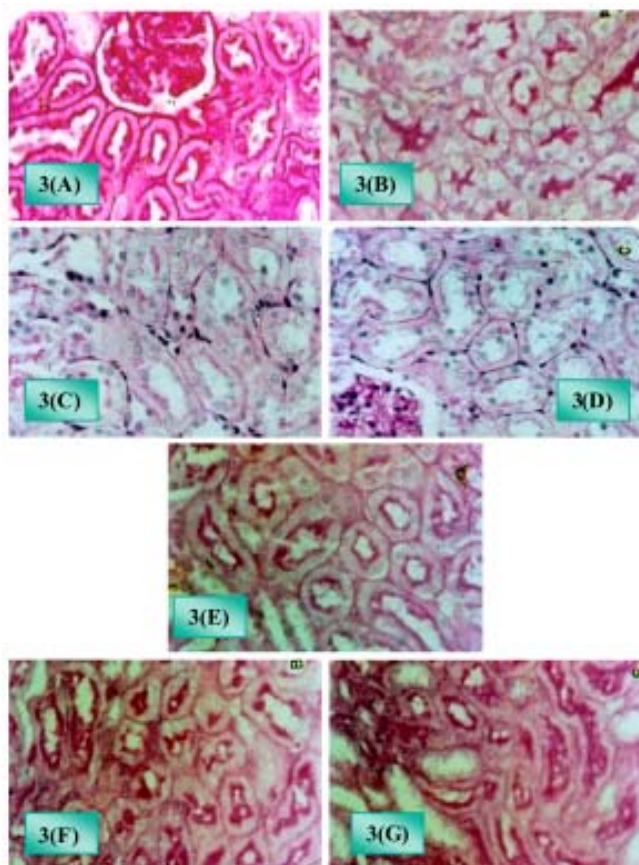


Figure 4: (PAS reaction x200). A. Section of kidney of control rat shows normal distribution of PAS positive materials. Notice the positive reaction in the renal corpuscles, the basement membrane of proximal and distal convoluted tubules and the brush border of the proximal convoluted tubules. B. Section of the kidney of rat treated with OA for two weeks shows a decrease PAS positive material. C. , D. Sections of the kidney of rat treated with OA for four and eight weeks shows a diminution in PAS reaction in renal corpuscles and the brush border of the proximal convoluted tubules. The basement membranes show faint stain as compared with control. E. Section of the kidney of rat treated with ginseng and OA in combination for two weeks shows an increase in PAS positive materials in the brush borders of tubules and the basement membranes of the renal tubules. F. Section of the kidney of rat treated with ginseng and OA in combination for two weeks shows an increase in PAS positive materials in brush borders of tubule the basement membrane of the renal tubules. G. Section of the kidney of rat treated with ginseng and OA in combination for two weeks shows an increase in PAS positive materials in the renal corpuscles brush borders of tubules.

5) showed significant decrease in kidney cells of the ochratoxin groups after two, four and eight weeks ($P < 0.05$) by 12.5%, 15.38%, and 37.5% respectively. Figures 4- B, C, D showed decrease in kidney cells glycogen content in the ochratoxin groups after two, four and eight weeks as compared with the control group.

The injection of the rats with ginseng and ochratoxin led to significant increase in glycogen content after two, four, and eight weeks respectively (Table 1,

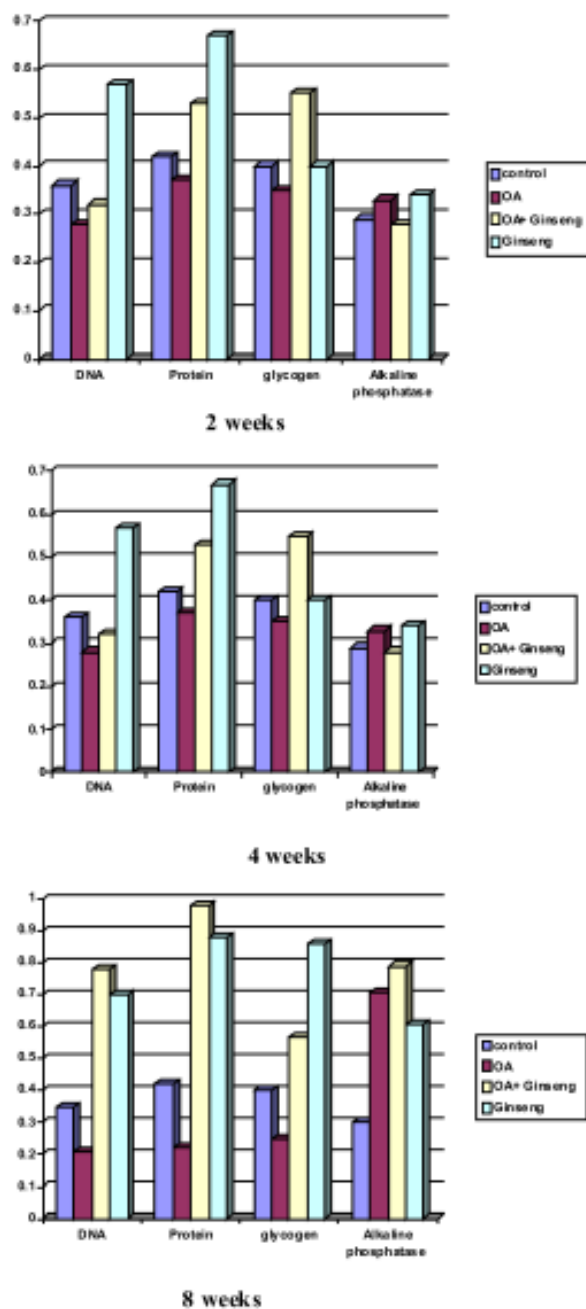


Figure 5: Optical density value of DNA, protein, glycogen content and alkaline phosphatase activity in kidney cells of male rats treated with OA and or ginseng after two, four and eight weeks of intraperitoneal treatment.

Figure 5). Figures 4- E, F, G showed an increase in kidney cells glycogen content in the ginseng and ochratoxin groups after two, four and eight weeks as compared with the OA group.

In the control rat high alkaline phosphatase activity was observed in the lining cells of the tubules

mainly at their brush border (Table 1, Figure 5).

Alkaline phosphatase activity in kidney cells (Table 1, Figure 5) of the rats given OA increased significantly ($P < 0.05$) to 136.66% after eight weeks.

In addition, the optical density value of alkaline phosphatase activity was significantly higher in the group of rat treated with ginseng and ochratoxin than that of control especially after eight weeks ($P < 0.05$) by 103.33%.

The injection of the rats with ginseng only led to significant elevation of DNA, protein content and glycogen in kidney cells after two, four and eight weeks. The alkaline phosphatase activity increased significantly due to ginseng treatment after four and eight weeks (Table 1, figure 5).

Morphometric results

Morphometric examination of kidney of rats treated with ginseng showed no significant difference in glomerular area as compared with control (Table 2). It was found that glomerular area of kidney of rats treated with OA showed significant decrease ($P < 0.05$) as compared with control after two, four and eight weeks of treatment (Table 2). While, a significant increase ($P < 0.05$) in glomerular area was recorded in kidney of rats that treated with OA and ginseng for two, four and eight

Table 2: Glomerular area (μ^2) and Damage area (μ^2) of control, ochratoxin A and ginseng in kidney cells of male rats after two, four and eight weeks of intraperitoneal treatments.

		Glomerular area (μ^2)	Damage area (μ^2)
2 weeks	Control	577.2 \pm 12.14	0
	Ginseng	590.97 \pm 15.70	0
	OA	343.29 \pm 17.12 *	3212.23 \pm 128.81
	OA+ Ginseng	685.23 \pm 23.55**	1560.69 \pm 172.24*
4 weeks	Control	577.2 \pm 12.14	0
	Ginseng	525.32 \pm 21.06	0
	OA	343.29 \pm 17.12 *	
	OA+ Ginseng	568.58 \pm 23.00 **	1228.1 \pm 103.3*
8 weeks	Control	577.2 \pm 12.14	0
	Ginseng	583.71 \pm 23.15	0
	OA	343.29 \pm 17.12 *	
	OA+ Ginseng	527.12 \pm 15.50 **	1154.58 \pm 209.46*

* Significant difference as compared with control ($P < 0.05$), ** Significant difference as compared with OA ($P < 0.05$).

weeks as compared with that treated with OA only (Table 2).

Measurement of the damaged areas in kidney of rats treated with OA and ginseng showed a significant decrease ($P < 0.05$) after two, four and eight weeks of treatment as compared with that treated with OA only for the same periods (Table 2).

Discussion

Ochratoxin A was found to be extremely toxic on kidney. The histopathological and histochemical changes were all doses dependent. This in general is in agreement with the results of Mally et al [26].

In the present work, ochratoxin induced vacuolar degeneration and hyaline casts in kidney of rat after eight weeks. This is in agreement with Milicevic et al. [27]. The authors found that ochratoxin A induced moderate and obvious degenerative changes, swelling, vacuolar and lipophilic degeneration were the main changes in the tubular epithelial cells.

In contrary with Rasonyi et al. [28], necrotic cells and cell exfoliations in rat kidney treated with ochratoxin were noticed. No hyaline casts were noticed. According to Elaroussi et al. [29], the histopathological changes in the kidney of ochratoxin treated birds were mainly found in proximal convoluted tubules in the form of cloudy swelling and degeneration in the cytoplasm and pyknotic nuclei of PCT. In the present study the kidney of rats treated with OA for four weeks showed mononuclear cellular infiltration and haemorrhage in the interstitial tissue. These results go in agreement with Milicevic et al. [27]. They recorded that ochratoxin A caused moderate, marked hemorrhages of some renal cortical region occurred occasionally and mononuclear inflammatory infiltrate in the interstitium. The hemorrhage and congestion detected in the present study might be explained by hepatotoxic effect of ochratoxin on coagulation factor synthesis and/or its effect on blood platelets [30], and the cellular inflammatory noticed in the present study suggest an internal inflammatory reaction [14].

In recent studies on ochratoxin, Pfohl-Leszkowicz et al. [13]; EL-Khour and Atoui [12], found that the OTA caused tubular degeneration, focal tubular epithelial cells proliferation, glomerulonephrosis, tubulonephrosis in kidney of chicken.

The pathological changes observed in kidney of rats due to ochratoxin injection in the present work may be attributed to increase lipid peroxidation level and glutathione depletion [1, 31]. The results of Chakraborty and Verma [32] revealed a significant increase in lipid peroxidation as well as a decreased activity of enzymatic antioxidants (superoxide dismutase, catalase, glutathione peroxidase, glutathione reductase and glutathione transferase) and non-enzymatic antioxidants (glutathione and total ascorbic acid) in the kidney and liver of mice.

Ginseng showed noticeable improvement in tissues treated with Ochratoxin. Nishino et al. [33] reported that ginseng can increase body resistance to many harmful factors and protect tissue from damage and could inhibit lipid peroxidation of rat liver and kidney. Lee et al. [34] stated that ginseng may reduce cell damage induced by toxic substance and acts to stabilize cell membranes there by providing protection against toxic agents induced tissue injury.

Free radicals were produced by mycotoxin [35]. The free radical attack DNA and lead to cross linkages within the molecules [1].

In the present work, ochratoxin A caused sever depletion in DNA content in kidney cells. According to Wang and Groopman [36], mycotoxin produced chromosomal aberration, micronuclei, sister chromatid exchange and unscheduled DNA synthesis. Arlt et al. [37], Lebrun and Fultmann [38] stated that ochratoxin induced DNA single strand breaks (SSB) and DNA adducts. In addition, Obrecht-Pflumio and Dirheimer [39] reported that ochratoxin is metabolized to genotoxic metabolites which interact with DNA may cause genetic damage in both target tissue independent of direct covalent binding to DNA. According to Luhe et al. [40], the decrease cell proliferation could be due to OA toxicity, which alters transcriptional level of several genes known to be involved in DNA damage.

The present data further confirm oxidative stress as a key source of OA-induced DNA damage and provide additional evidence for a role of this mechanism in OA carcinogenicity [41]. Also, Sava et al [42] stated the OA caused an increased in oxidative stress and transient inhibition of oxidative DNA repair.

In the present work the injection of rats with ginseng and ochratoxin A in combination, led to increase in DNA content in comparison with group of rats treated with ochratoxin only. The injection of rats with ginseng only, led to a significant increase in DNA content in kidney cells. These effects may be due to the antioxidant nature of ginseng [33].

In the present work, ochratoxin decreased the protein content in kidney cells after two, four, and eight weeks. Schwerdt et al. [43] stated that ochratoxin is known to inhibit protein synthesis. Also, Diana et al. [44] suggested another mechanism of OA toxicity. The authors stated that the mechanism might be through OA disruption of protein synthesis and indirect impairment of the activity of several cellular enzymes. These effects can alter several cellular carbohydrate metabolisms. Increase in

protein content was noticed after treatment with ginseng and OA at different durations in comparison with OA alone. Zhang [23] reported that the treatment of ginseng caused increase amount of ribosome in rough endoplasmic reticulum in cells, reflecting their ability to protein synthesis.

With regards to the chemical structure, the OTA molecule represents a phenylalanine-dihydroisocoumarin derivative, which is very stable to both temperature and hydrolysis. Due to its structural analogy to the amino acid phenylalanine, the toxin is able to competitively inhibit tRNA phenylalanine synthetases and as a consequence protein synthesis is interrupted [45].

In the present experiment ochratoxin A caused significant decrease in glycogen content in kidney cells after two, four, and eight weeks. This result is in agreement with Kozaczynski [46] who stated that no glycogen content was detected in kidney treated with ochratoxin. Dwivedi and Burns [47] noticed enzymatic inhibition of glycogenolysis in ochratoxin toxicosis and this could be due to excess glycogen observed in the kidney of rat. According to Sandhu et al. [48], the treatment of chicks with OA led to increase in mucopolysaccharides (MPS) in liver and kidney tissues. Increase in glycogen content was noticed after treatment with ginseng and OA at different durations in comparison with OA alone. This is in agreement with Zhang [23] who stated that ginseng had a protective effect on mitochondria that appeared less damaged.

In the present study, increased reaction for alkaline phosphatase activity was observed after four and eight weeks. This is in disagreement with Kozaczynski [46] who noticed a decrease in alkaline phosphatase activity in the brush border of renal tubules of male chickens treated with ochratoxin.

It seems that kidney is a target organ of the ochratoxin, since the toxin affects the histology and histochemistry of kidney. On the other hand, ginseng reduces many harmful effects of ochratoxin in kidney as indicated by the histopathological, histochemical and morphometric studies.

References

1. Baudrimant I, Sostaric B, Yenot C, Betbeder AM, DanoDjedje S, Sanni A, Steyn PS, Creppy EE. Aspartam prevents the karyomegally induced by ochratoxin A in rat kidney. Arch Toxicol. 2001;75:176-83.

2. AL-Anati L and Petzinger E. Immunotoxic activity of ochratoxin A. *J Vet Pharmacol Ther*. 2006; 29:79-90.
3. Magnoli C, Hallak C, Astoreca A, Ponsone L, Chiacchiera S, Dalcero A. Occurrence of ochratoxin A-producing fungi in commercial corn kernels in Argentina. *Mycopathologia*. 2006a; 161:53–8.
4. Rosa CAR, Ribeiro JMM, Fraga MJ, Gatti M, Cavaglieri LR, Magnoli CE, Dalcero AM, Lopes CW. Mycoflora of poultry feeds and ochratoxin-producing ability of isolated *Aspergillus* and *Penicillium* species. *Vet Microbiol*. 2006; 113:89-96.
5. Magnoli C, Hallak C, Astoreca A, Ponsone L, Chiacchiera SM, Palacio G, Dalcero A. Surveillance of toxigenic fungi and ochratoxin A in feedstuffs from Cordoba province, Argentina. *Vet Res Commun*. 2005; 29:431-45.
6. Pardo E, Marín S, Ramos AJ, Sanchis V. Occurrence of ochratoxigenic fungi and ochratoxin A in green coffee from different origins. *Food Sci Technol Int*. 2004; 10:45-49.
7. Hurst WJ, Martin RA Jr. High-performance liquid chromatographic determination of ochratoxin A in artificially contaminated cocoa beans using automated sample clean up. *J Chromatogr A*. 1998; 810:89-94.
8. Magnoli C, Violante M, Combina M, Palacio G, Dalcero A. Mycoflora and ochratoxin-producing strains of *Aspergillus* section Nigri in wine grapes in Argentina. *Lett Appl Microbiol*. 2003; 37:179-84.
9. Magnoli C, Astoreca A, Ponsone L, Combina M, Palacio G, Da Rocha Rosa CA, Dalcero AM. Survey of mycoflora and ochratoxin A in dried vine fruits from Argentina markets. *Lett Appl Microbiol*. 2004; 39:326-31.
10. Magnoli C, Astoreca A, Ponsone ML, Fernández-Juri MG, Barberis C, Dalcero A. Ochratoxin A and *Aspergillus* section Nigri in peanut seeds at different months of storage in Córdoba, Argentina. *J Sci Food Agric*. 2006; 86:2369-73.
11. Medina A, Jiménez M, Gimeno-Adelantado JV, Valle-Algarra FM, Rufino M. Determination of ochratoxin A in beer marketed in Spain by liquid chromatography with fluorescence detection using lead hydroxyacetate as a clean-up agent. *J Chromatogr A*. 2005; 1083: 7-13.
12. EL-Khour A, Atoui A. Ochratoxin A: General overview and actual molecular status. *Toxins*. 2010; 2:461-93
13. Pfohl-Leschkowicz A, Manderville RA. Ochratoxin A: An over view on toxicity and carcinogenicity in animals and humans. *Mol Nutr Food Res*. 2007; 51:61-99.
14. Anke L, Heinz H, Ute B, Theodor D, and Hans J. A new approach in studying ochratoxin A (OAT)-induced nephrotoxicity expression profiling in vivo and vitro. *Sciences*. 2003; 73:315-28.
15. Marquadt RR, Frohlich AA. A review of recent advances in understanding ochratoxicosis. *J Anim Sci*. 1992; 70:3968-88.
16. Wen J, Zimmer EA. Phylogeny and biogeography of *Panax* L. (the ginseng genus, araliaceae): inferences from ITS sequences of nuclear ribosomal DNA. *Mol Phylogenet Evol*. 1996; 6:167-77.
17. Wang CZ, Mehendale SR, Yuan CS (2007) Commonly used antioxidant botanicals: active constituents and their potential role in cardiovascular illness. *Am J Chinese Med*. 2007; 35: 543-58.
18. Gardiner P, Graham R, Legedza AT, Ahn AC, Eisenberg DM, Phillips RS. Factors associated with herbal therapy use by adults in the United States. *Alternative Therapies in Health and Medicine*. 2007; 13:22-29.
19. Barnes PM, Bloom B, Nahin R. Complementary and alternative medicine use among adults and children: United States, 2007. *CDC National Health Statistics Report* 12. 2008.
20. Keum YS, Park KK, Lee JM, Chun KS, Park JH, Lee SK, Kwon H, Surh YJ. Antioxidant and anti-tumor promoting activities of the methanol extract of heat-processed ginseng. *Cancer Letter*. 2000; 150: 41-48.
21. Hasegawa H, Suzuki R, Nagaoka T, Tezuka Y, Kadota S, Saiki I. Prevention of growth and metastasis of murine melanoma through enhanced natural-killer cytotoxicity by fatty acid-conjugate of protopanaxatriol. *Biological & Pharmaceutical Bulletin*. 2002; 25: 861-66.
22. Kaneko H, Nakanishi K. Proof of the mysterious efficacy of ginseng: Basic and clinical trials: Clinical effects of medical ginseng, Korean red ginseng: specifically, its anti-stress action for prevention of disease. *J of Pharmacol Sci*. 2004; 95:158-62.
23. Zhang OY. Protective effects of ginsenosides on warm ischemic damage of the rabbit kidney. *Ching Hua I Hsueh Tsa Chih Taipei*. 1992; 42: 84-95.
24. Romero SM, Pinto VF, Patriarca A, Vaamonde G. Ochratoxin A production by a mixed inoculation of *Aspergillus carbonarius* at different conditions of water activity and temperature. *International J of Food Microbio*. 2010; 140:277-81.
25. Moré J, and Galtier P. Toxicity of ochratoxin A. I. Embryotoxic and teratogenic effect in rats. *Ann Réch Vet*. 1974; 5:167-78
26. Mally A, Völkel W, Amberg A, Kurz M, Wanek P, Eder E, Hard G, Dekant W. Functional, biochemical, and pathological effects of repeated oral administration of ochratoxin A to rats. *Chem Res Toxicol*. 2005; 18:1242-52.
27. Milicevic DR, Juric VB, Dakovic A, Jovanovic M, Stefanovic SM, Petrovic ZI. Mycotoxin porcine nephropathy and spontaneous occurrence of ochratoxin A residues in kidney of slaughtered swine. *Nat Sci Matica Srpska Novi Sad*. 2009; 116:81-90.

28. Rasonyi T, Schlatter J, Dietrich DR. The role of alpha2u-globulin in Ochratoxin A induced renal toxicity and tumors in F344 rats. *Toxicol Lett.* 1999;104: 83-92.
29. Elaroussi MA, Mohamed FR, Elgendy MS, EL Barkouky EM, Abdou AM, Hatab MH. Ochratoxicosis in broiler chickens: Functional and histological changes in target organs. *International Journal of Poultry Science.* 2008; 7:414-22
30. Obrein E, Dietrich DR. Ochratoxin A: The continuing enigma. *Critical Reviews in Toxicology.* 2005; 35:33-60.
31. Meki AR, Hussein A. Comparative Melatonin reduces oxidative stress induced by ochratoxin A in rat liver and kidney. *Toxicol & Pharmacol.* 2001; 130:305-13.
32. Chakraborty D, Verma R. Ameliorative effect of *Emblica officinalis* aqueous extract on ochratoxin-induced lipid peroxidation in the kidney and liver of mice. *Int J Occup Med Environ Health.* 2010; 23:63-73.
33. Nishino H, Tokuda H, Masuda M, Satomi Y, Okada Y, Okuyama T. Cancer chemoprevention by ginseng in mouse liver and other organs. *J. Korean. Med Sci Supp S.* 2001; 66-69.
34. Lee HC, Hwang SG, Lee YG, Sohn HO, Lee DW, Hwang SY, Moon JY. In vivo effects of *Panax ginseng* extracts on the cytochrome P450-dependent monooxygenase system in the liver of 2, 3, 7, 8- tetrachlorodibenzo-p-dioxin-exposed guinea pig. *Life Science.* 2002; 71: 957-69.
35. Petkova-Bocharova T, Stoichev II, Chernozemsky IN, Castegnaro M, Phohleszkowicz A. Formation of DNA adducts in tissues of mouse progeny through transplacental contamination and/or lactation after administration of a single dose of ochratoxin A to the pregnant mother. *Environ Mol Mutagen.* 1998;32:155-62.
36. Wang JS, Groopman JD. DNA damage by ochratoxin A. *Chem Biol Interact.* 1999; 127: 29-44.
37. Arlt VM, Pfohl-Leszkwicz A, Cosyns J, Schmeiser HH. Analysis of DNA adducts formed by ochratoxin A and aristolochic acid in patients with Chinese herbs nephropathy. *Mut Res.* 2001; 494:143-50.
38. Lebrun S, Fullmann W. Detection of Ochratoxin A induced DNA damage in MDCK cells by alkaline single cell gel electrophoresis. *Arch Toxicol.* 2002; 75: 734-41.
39. Obrecht-Pflumio S, Dirheimer G. In vitro DNA and GMP adducts formation caused ochratoxin A. *Chem Biol Interact.* 2000;127:29-44
40. Luhe A, Hildebrand H, Bach U, Dingermann T, Ahr HJ. A new approach to studying ochratoxin A (OTA)-induced nephrotoxicity: expression profiling in vivo and in vitro employing cDNA microarrays. *Toxicol Sci.* 2003;73:315-28.
41. Cavin C, Delatour T, Marin-Kuan M, Fenaille F, Holzhäuser D, Guignard G, Bezençon C, Piguet D, Parisod V, Richoz-Payot J, Schilter B. Ochratoxin A-mediated DNA and protein damage: roles of nitrosative and oxidative stresses. *Toxicol Sci.* 2009; 110:84-94.
42. Sava V, Reunova O, Velasquez A, Harbison R, Sánchez-Ramos J. Acute neurotoxic effects of the fungal metabolite ochratoxin-A. *Neurotoxicol.* 2006; 27:82-92.
43. Schwerdt G, Freudinger R, Silbernagl S, Gelke M. Ochratoxin A-binding protein in rat organs and plasma and in different cell lines of the kidney. *Toxicology.* 1999; 135:1-10.
44. Diana R, Abalo C, Yves-Jacques S, Yvan L. toxicokinetics and toxicodynamics of ochratoxin A, an update. *Chemico Biological Interactions.* 2006; 70:3968-88.
45. Dirheimer G, Creppy EE. Mechanism of action of ochratoxin A. *IARC Sci Publ.* 1991;115:171-186.
46. Kozaczynski W. Experimental Ochratoxicosis A in Chickens Histo-pathological and histochemical study. *Arch Vet Pol.* 1994; 34:205-19.
47. Dwivedi P, Burns RB. Pathology of ochratoxicosis A in young broiler chick. *Res Vet Sci.* 1984; 36:92-103.
48. Sandhu B, Singh H, Singh B. Pathological studies in broiler chicks fed a aflatoxin or ochratoxin and inoculated with inclusion body hepatitis virus singly and in concurrence. *Vet Res Commun.* 1995; 19:27-37.